Oklahoma Heart Institute

VOLUME 12 | NUMBER 1 | SPRING 2017

Risk Stratification for Prevention of Heart Attacks and Strokes

The Role of OHI in the Treatment of Lung Cancer

Fractional Flow Reserve on Coronary CT Angiography

Who's Flying Your Plane? The OHI Executive Health Program

Intro to the Hybrid Algorithm & Coronary CTO Vocabulary

Whole Heart Healthy Foods

...and More!

Oklahoma Heart Institute

Oklahoma Heart Institute Hospital
1120 Utica Ave., Tulsa, OK 74104
P) 918.574.9000

Oklahoma Heart Institute
at Utica Physicians Offices
1265 S. Utica Ave., Suite 300, Tulsa, OK 74104
P) 918.592.0999 • F) 918.595.0208

Oklahoma Heart Institute
at Southpointe Physicians Offices
9228 S. Mingo Road, Suite 200, Tulsa, OK 74133
P) 918.592.0999 • F) 918.878.2408

Hillcrest Hospital South
8801 S. 101st E. Ave., Tulsa, OK 74133
P) 918.294.4000

Published by Oklahoma Heart Institute
Edited by Newsgroup Communications, Tulsa, OK
Designed by Amanda Watkins
For advertising information contact:
Elaine Burkhardt at 918.749.2506
newsgroupcom@gmail.com
visit our website at www.oklahomaheart.com

The Oklahoma Heart Institute Magazine is mailed directly to referring physicians and other referring health care professionals in the Tulsa area and is also available in our patient waiting rooms.

features

to our readers

Prevention and early diagnosis still remains the best therapy for cardiovascular and pulmonary diseases. This year's spring Oklahoma Heart Institute Magazine highlights the value of prevention as the optimal therapy for the treatment of cardiovascular disease. Dr. Frank Gaffney discusses the OHI Executive Health Program. He highlights the rationale behind the value of prevention

Each year in the United States there are between seven hundred thousand and a million patients who experience a heart attack. Clearly, screening for patients at risk is not optimal. Dr. Victor Cheng discusses the latest option for screening for the presence of coronary artery disease. He highlights the role of coronary CT angiography combined with fractional flow reserve (FFR) to identify not only blockages in the blood vessels to the heart, but also to indicate which blockages are hemodynamically significant.

In the area of lung cancer, early detection can lead to a cure. Dr. Michael Phillips discusses the use of CT screening for the early detection of lung cancer.

As techniques and equipment continue to advance in the field of Interventional Cardiology, fewer and fewer patients end up needing bypass graft surgery for the treatment of their coronary artery disease. Dr. Raj Chandwaney discusses the expanding role of interventional cath lab techniques for opening coronary chronic total occlusions. This helps many patients avoid the more invasive surgical procedures for the treatment of their coronary artery disease.

We hope that you enjoy the articles and welcome any comments or suggestions regarding the magazine content.

Sincerely,

Wayne N. Leimbach, Jr., MD
Publisher/Editor, Oklahoma Heart Institute Magazine

ON THE COVER
"Sunrise at Centennial Park"
Photo by Stephen Pier

Risk Stratification for Prevention of Heart Attacks and Strokes

By Lynn Cofer-Chase, MSN, RN, FNLA, FAHA, FPCNA

The Oklahoma Heart Institute's Lipid & Prevention Center has been at the forefront of cardiovascular risk reduction, combining advanced therapies and aggressive lifestyle modifications to halt disease progression and work to reverse it. Yet in Oklahoma and nationwide, heart disease remains the number one killer of both women and men. The JUPITER study showed that half of adults who experience a cardiac event have normal LDL-cholesterol levels (under 130 mg/dL), indicating lipids only indicate part of a patient's risk[1] or goals need to be lower.

Damage to a body's vasculature not only from cholesterol, but by a myriad of risk factors, ignites the body's response to injury called inflammation. Each one of our bodies is affected by risk factors differently. We know that our inflammation response will undoubtedly be unique to individuals as well. Testing for inflammation allows clinicians to identify where patients are on a spectrum of risk, and they can then treat patients based on factors believed to be driving disease.

Co-founder and Chief Medical Officer of Cleveland HeartLab, Marc Penn, MD, PhD, FACC designed an approach using inflammatory biomarkers that helps practitioners determine where patients fall on a spectrum of risk. The spectrum can be stratified into 3 categories: Risk of Disease, Presence of Disease, and Disease Activity. Each category helps clinicians capture the entire picture of risk by combining lipids and inflammation to plan more efficient, personalized treatment regimens.

> **"This combination of inflammatory biomarkers warns of additional risks in real time, so that we can be more aggressive earlier in those who are at highest risk."**
> **– Eric Auerbach, M.D.**

- **Risk of Disease** utilizes tests to measure F2 Isoprostanes and Oxidized LDL. F2 Isoprostanes is the 'gold standard' for measuring oxidation due to lifestyle. Elevations in this biomarker have been shown to increase risk of atherosclerosis[2]. OxLDL measures oxidation of LDL cholesterol, which can increase risk of developing acute coronary syndrome[3].
- **Presence of Disease** is indicated by: Microalbumin (MACR), Asymmetric dimethylarginine (ADMA), and High-sensitivity C-Reactive Protein (hsCRP). Slight elevations (3.9 mg/g for men and 7.5 mg/g for women) in the microalbumin/creatinine ratio (MACR) are a structural warning of hidden disease damaging the endothelium. Studies report these MACR results portend a 3-fold increase in cardiovascular events. Rising MACR levels warn of increased risk of cardiovascular mortality[4,5]. ADMA, a chemical marker of endothelial dysfunction associated with impaired synthesis of nitric oxide, can also warn of the presence of cardiovascular disease. An elevated ADMA was linked to a 2.5x increased risk of CVD events and CVD mortality[6-8]. A chronic elevation of a general marker of inflammation, hsCRP (≥2 mg/dL and <10 mg/dL), has been positively correlated with increased incidence of major cardiovascular events[2]. The 2013 ACC/AHA guideline for cardiovascular risk assessment showed strong evidence linking hsCRP with cardiovascular events and noted the contributions of other inflammatory biomarkers associated with ischemic vascular disease based on data from the Risk Factor Collaboration[9].
- **Disease Activity** identifies the inflammation markers called Myeloperoxidase (MPO) and Lipoprotein-associated phospholipase A_2 (Lp-PLA_2) that can indicate near term risk. MPO has been shown to outperform hsCRP in its ability to predict acute coronary syndrome, but when combined with hsCRP is a much better predictor of cardiovascular mortality than either marker alone[10,11]. Additionally, elevations in Lp-PLA_2, a known predictor

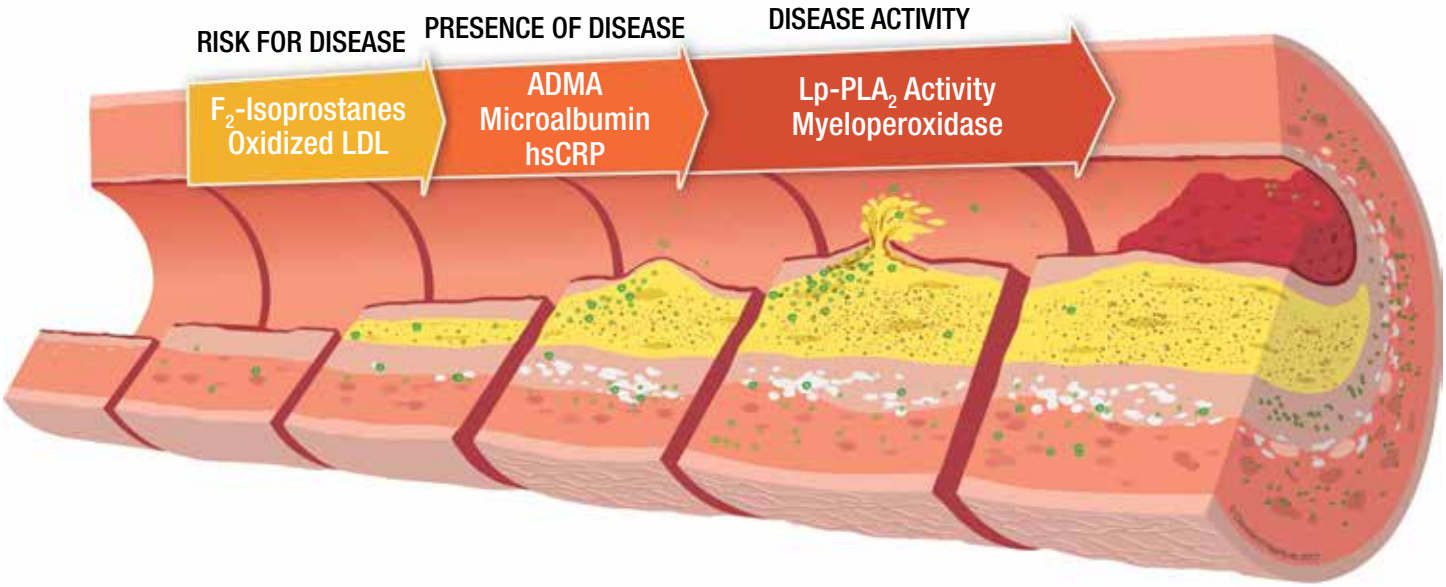

of both heart attack and stroke risk, when combined with hsCRP warn of increased risk of ischemic stroke as much as 10-fold[12]. MPO and Lp-PLA_2 "define distinct physiologies of plaque vulnerability[13]". Experts in prevention suggest that the use of a panel of inflammatory biomarkers that addresses both systemic (hsCRP) and more vascular specific markers that reveal evidence of unstable plaque (MPO and Lp-PLA_2) could provide "optimal risk prediction[14]." Recent data from CHL demonstrates that of more than 30,000 patients tested in the 2nd half of 2016 for both MPO and Lp-PLA2 Activity, 10.5% had elevated Lp-PLA_2, 7.0% had elevations in MPO, and only 1.3% had elevations in both MPO and Lp-PLA_2[15].

According to Penn, "By the time patients are 60 years old, half have some evidence of cardiovascular disease. Controlling cholesterol plays a large role in preventing events and standard lipid tests provide a view of one's life long risk. Patients can now have access through the Oklahoma Heart Institute to simple blood and urine tests that measure inflammation and stratify patients to provide a more complete picture of cardiovascular risk."

Board certified cardiologist Dr. Eric Auerbach believes that "by combining inflammation and lipid testing, the Oklahoma Heart Institute is continuing its longstanding multi-faceted approach as a Center of Excellence - helping patients manage complex disorders based on science based evidence. Inflammation testing helps me get a more complete picture of my patients' endothelial health and cardiovascular risk, so I can focus on targeted prevention and treatment, further reducing heart attack and strokes in our patient population."

Lynn Cofer-Chase is the Clinical Lipid Specialist/ Manager of Clinical Education for Cleveland HeartLab. She is the former co-director of a heart disease prevention center noted as a model of excellence in the NCEP ATP III guidelines, speaks nationally, and has authored numerous professional publications. She is currently President of the Accreditation Council for Clinical Lipidology.

References

1. Ridker PM, Danielson E, Fonseca FAH, et al. Rosuvastatin to prevent vascular events in men and women with elevated C-reactive protein. N Engl J Med. 2008;359:2195-2207.
2. Schwedhelm E et al. Urinary 8-iso-prostaglandin F2alpha as a risk marker in patients with coronary heart disease: A matched case-control study. Circulation. 2004; 109: 843-848.
3. Ehara S et al. Elevated levels of oxidized low density lipoprotein show a positive relationship with the severity of acute coronary syndromes. Circulation. 2001; 103: 1955-1960.
4. Gerstein HD, Mann JFE, Vi O, et al. Albuminuria and risk of cardiovascular events, death, and heart failure in diabetic and non-diabetic individuals. JAMA 2001;286:421-426.
5. Arnlov J, Evans JC, Meigs JB, et al. Low-grade albuminuria and incidence of cardiovascular disease events in non-hypertensive and non-diabetic individuals. Circ 2005:112:969-975.
6. Boger RH, Sullivan LM, Schwedhelm E, et al. Plasma asymmetric dimethylarginine and incidence of cardiovascular disease and death in the community. Circ 2009;119:1592-1600.
7. Schnabel R, Blankenberg S, Lubos E, et al. Asymmetric dimethylarginine and risk of cardiovascular events and death in patients with coronary artery disease: Results of the AtheroGene Study. Cir Res 2005;97:e53-59.
8. Meinitzer A, Seelhorst U, Wellnitz B, et al. Asymmetric dimethylarginine independently predicts total and cardiovascular mortality in individuals with angiographic coronary artery disease (The Ludwigshafen Risk and Cardiovascular Health Study). Clin Chem 2007;55:273-283.
9. Goff DC Jr, Lloyd-Jones DM, Bennett G, et al. 2013 ACC/AHA guideline on the assessment of cardiovascular risk: a report of the American College of Cardiology/American Heart Association Task Force on practice guidelines [published online ahead of print November 12, 2013]. Circulation. http://dx.doi.org/10.1161/01.cir.0000437741.48606.98. Assessed March 19, 2014.
10. Ndrepepa G, Braun S, Mehilli J, et al. Myeloperoxidase level in patients with stable coronary artery disease and acute coronary syndromes. Eur J Clin Invest. 2008;38:90-96.
11. Heslop CL, Frohlich JJ, Hill JS. Myeloperoxidase and C-reactive protein have combined utility for long-term prediction of coronary mortality after coronary angiography. JACC 2010;55:1102-1109.
12. Ballantyne CM, Hoogeveen RC, Bang H, et al. Lipoprotein-associated phospholipase A2, high-sensitivity C-reactive protein, and risk for incident ischemic stroke in middle aged men and women in the Atherosclerosis Risk in Communities (ARIC) study. Arch Intern Med. 2005;165:2479-2484.
13. Penn MS, Klemes AB. Multimarker approach for identifying and documenting mitigation of cardiovascular risk. Future Cardiol. 2013:9:497-506.
14. Toth PP, McCullough Pa, Wegner MS, Colley KY. Lipoprotein-associated phospholipase A2: role in atherosclerosis and utility as a cardiovascular biomarker. Expert Rev Cardiovas Ther. 2010;8:425-438.
15. Cleveland HeartLab. 2017. Unpublished data.

The Role of Oklahoma Heart Institute in the Treatment of Lung Cancer

By Michael R. Phillips MD

Lung cancer remains the top cause of cancer death in men and women in the United States and has been so for the last several years. The cause of death lies mainly in its late detection, as most are too advanced for curative treatment once the diagnosis has been made. Early detection is the best form of intervention, and, as such, multiple national initiatives have been implemented to address this issue. The United States Preventative Task Force has therefore recommended that smokers, age 55-80, undergo a low-dose CT scanning every year. Most Medicare plans have agreed to cover the cost of this screening and ask your doctor if you are eligible for this opportunity. If smokers have quit within the last 15 years but smoked heavily prior to this time, CT scanning is also recommended. Second-hand smoke exposure also raises the level of risk for lung cancer. For example, spouses married to heavy smokers have a 20-30% higher risk of developing lung cancer during their lifetime, versus spouses not married to heavy smokers.

Figure 2

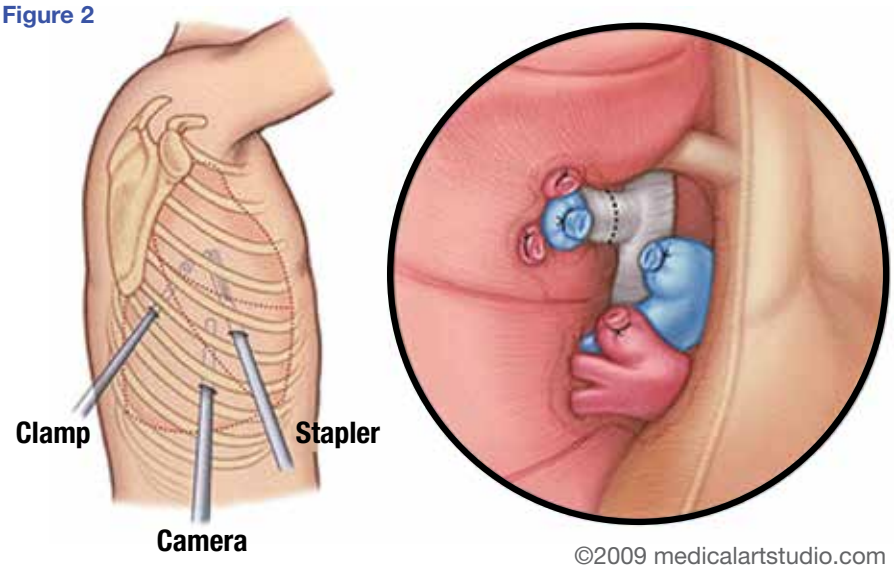

Lung cancer survival rates are clearly linked to early diagnosis and treatment, as outlined below (Table 1, diagram for survival rates for stages of lung cancer). In summary, the chances of survival are greater than 50% at 5 years for early detection and surgery, compared to less than 4% if advanced stages are identified at initial presentation.

DIAGNOSIS AND TREATMENT

The doctors at Oklahoma Heart Institute work closely with our referring, primary, pulmonology and oncology physicians to provide timely evaluation and treatment for pulmonary malignancy. Our goal is to minimize risks and provide diagnosis and treatment of lung cancer within 2-3 weeks of primary evaluation. This treatment may vary depending on stage and initial presentation, but, overall, we believe earlier intervention is better for patients. By optimizing cardiac risk, we can provide the best possible long-term outcomes. Our cardiologists at Oklahoma Heart Institute use state-of-the-art magnetic resonance imaging and coronary artery CT scanning to further identify coronary lesions in a noninvasive way, if standard treadmill testing suggests possible significant blockages. Once cardiac risks have been optimized, surgeons at Oklahoma Heart Institute offer a wide variety of surgical approaches for the diagnosis and treatment of early-stage lung cancer. We provide mediastinoscopy and video-assisted thoracoscopy (VATS) for diagnosis and treatment of early lung cancers.

Segmental resections, or limited removal of lung tissue, can also be performed safely at Oklahoma Heart Institute with video-assisted thoracoscopy or a minimally invasive muscle sparing approach (Figure 2). For advanced cancers requiring extensive lung removal, we use the mini thoracotomy with muscle-sparing technique. This approach provides the best staging techniques for lymph node involvement and spread of disease.

Table 1

Stage	NSCLC: 5-Year Survival Rates
Stage 1A	49-75%
Stage 1B	45-55%
Stage 2A	30-50%
Stage 2B	31-40%
Stage 3A	14-35%
Stage 3B	2-5%
Stage 4	<1%

Modified from: Detterbeck et al, 2009

Multiple studies have shown that all the described procedures above are equal in outcomes with regard to return to work, postoperative length of stay and operative time. These techniques have a proven safety, reliability and long-term survival track record. The oncologists also provide state-of-the-art immunotherapy to provide targeted chemotherapy post procedure, should it be required. Immunotherapy, or tumor-targeted chemotherapy, can also provide the best possible outcome for patients with minimal side effects. Our colleagues in pulmonology work closely with the surgeons regarding diagnosis, treatment and postoperative management by utilizing state-of-the-art endobronchial ultrasound techniques to optimize postoperative care. CyberKnife is a novel therapy, which utilizes high-dose beam radiation therapy, and this can be offered as a successful adjunct for patients with cancers deemed unresectable by a surgeon. This technique is performed by our colleagues in radiation oncology.

At Oklahoma Heart Institute, we are excited to be part of a comprehensive care profile for our patients that involve a multifaceted approach with our colleagues in their respective specialties. This technique will continue to provide optimal outcomes for our patients and provide the earliest detection possible. For further information regarding our detection programs and diagnosis evaluation, please contact us at any time at the following numbers: Oklahoma Heart Institute 918-749-6400 or 918-592-0999; Lung Cancer Screening Program 918-579-5864; Radiation Oncology 918-579-8200.

Dr. Phillips is a Cardiovascular Thoracic Surgeon at Oklahoma Heart Institute.

The doctors at Oklahoma Heart Institute work closely with our referring, primary, pulmonology and oncology physicians to provide timely evaluation and treatment for pulmonary malignancy.

Still Pictures Get Dynamic: Fractional Flow Reserve on Coronary CT Angiography

By Victor Cheng, MD, FACC, FSCCT
Director, Cardiovascular CT, Oklahoma Heart Institute

To achieve symptomatic benefit or heart attack risk reduction from coronary artery stenting and bypass surgery, patients should demonstrate obstructive coronary artery disease (CAD, defined as at least 50% diameter narrowing from coronary artery plaque) in at least one major coronary artery and some adverse clinical sequelae directly due to the disease, such as heart attack, angina, weakened left ventricular function, ventricular arrhythmia, or detectable reduction in blood flow to the myocardium supplied by the diseased artery (termed "coronary artery hypoperfusion" in this article). Reliable detection of coronary artery hypoperfusion in the setting of obstructive CAD is tremendously valuable. It is often present before other problems emerge and, in uncertain clinical situations, helps resolve whether chest pain or breathlessness is due to CAD. These features have made coronary artery hypoperfusion the main driving force for advancing contemporary noninvasive testing for CAD.

The current gold standard for diagnosing coronary artery hypoperfusion is fractional flow reserve (FFR) measurement, obtained by placing a specialized guide wire in the diseased coronary artery. This is most often done immediately after invasive catheter-based coronary angiography has found obstructive CAD. Performance of gold standard FFR requires intravenous administration of a coronary artery vasodilator, usually adenosine, to generate maximum blood flow throughout the coronary tree so that pressure in the coronary arteries becomes predictably proportional to flow. A pressure-sensitive guide wire is then advanced into the coronary artery until its measuring tip is positioned distal to the coronary artery obstruction (see Figure 1). Dividing the simultaneously measured fluid pressure distal to the obstruction into a "normal" reference pressure, usually at the aortic root or the undiseased beginning of the coronary artery, generates FFR. Normal coronary arteries generate ratios close to 1.0. FFR < 0.8 is considered probably abnormal, and < 0.75 is definitely abnormal. These numerical cutoffs

Figure 1

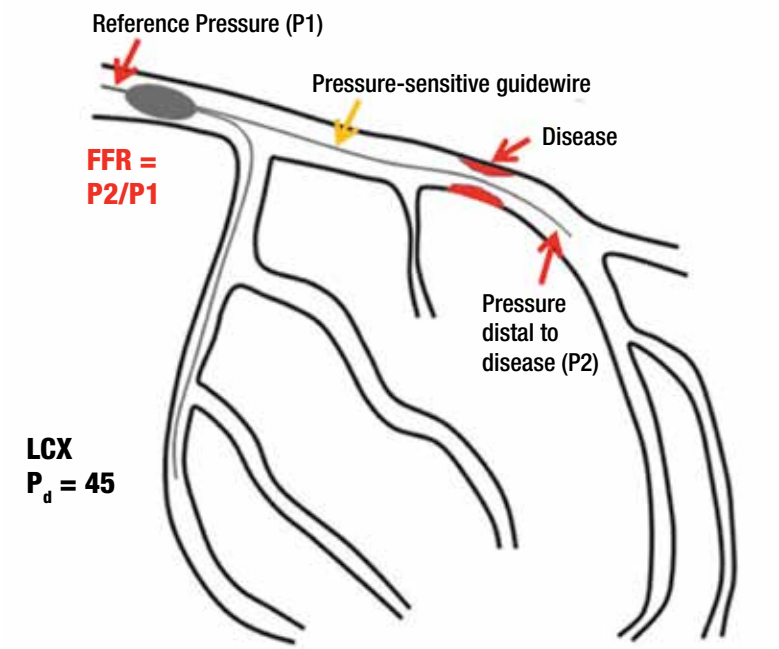

Schematic of catheter-based measurement of fractional flow reserve (FFR). The pressure-sensitive guidewire is advanced until its distal measuring end is past the obstruction. Pressures at the distal end (P2) and reference position (P1) are then simultaneously measured during maximum coronary blood flow induced by intravenous vasodilator infusion.
The ratio of P2 to P1 equals FFR.

Figure 2

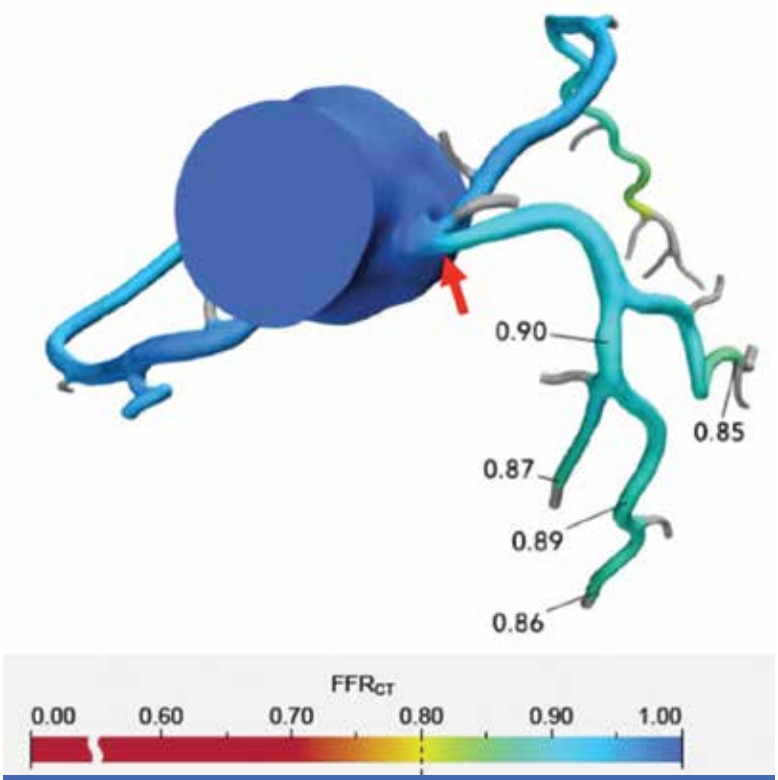

FFR-CT map of the major coronary arteries in a patient with nearly 50% diameter narrowing at the ostium of the left anterior descending artery (red arrow). FFR stays > 0.80 throughout the artery, indicating absence of coronary artery hypoperfusion.

Figure 3

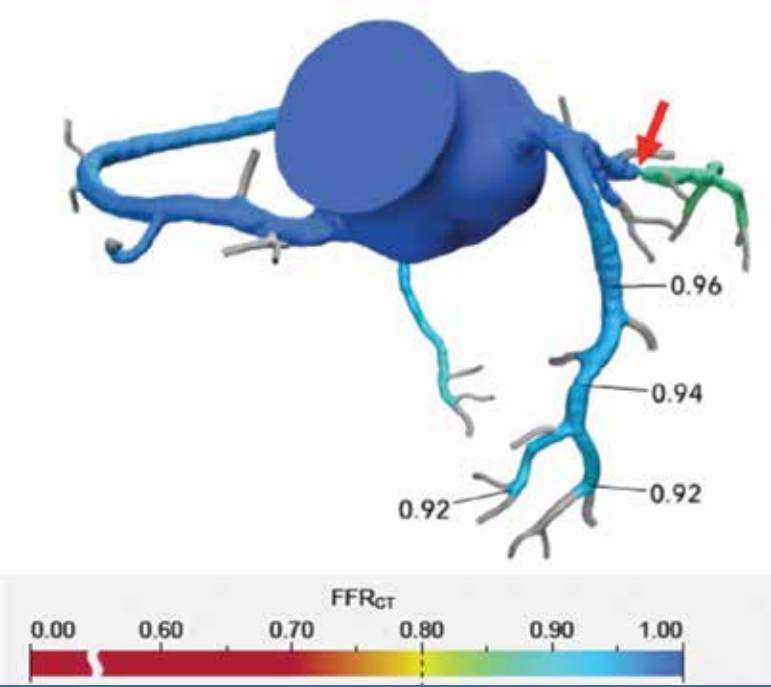

FFR-CT map in a patient with 50-69% diameter obstructive disease in the left circumflex artery (red arrow). FFR stays > 0.80 distal to the disease (green color), indicating absence of coronary artery hypoperfusion.

The current gold standard for diagnosing coronary artery hypoperfusion is fractional flow in reserve (FFR) measurement, obtained by placing a specialized guide wire in the diseased coronary artery.

identified patients in whom elective, non-urgent, coronary artery stenting and bypass surgery can be safely deferred in the landmark FAME and FAME-2 trials.[1,2]

Simply finding obstructive CAD on catheter-based coronary angiography does not correlate well with FFR. For example, in the FAME trial, two-thirds of arteries with 50-69% narrowing and one-fifth of arteries with 70-90% narrowing exhibit normal FFR.[1] Coronary CT angiography (CTA), while highly accurate in diagnosing obstructive CAD, essentially replicates what invasive coronary angiography would reveal. Therefore, it has the same exact difficulty in predicting FFR.[3] Continued increase in coronary CTA use has raised the concern that, as more cases of obstructive CAD are identified, more patients without coronary artery hypoperfusion end up undergoing invasive coronary angiography, causing some to receive unnecessary angioplasty and stent treatment.[4,5]

Extracting a useful measure of coronary artery hypoperfusion from coronary CTA has been pursued for years. These efforts have ultimately resulted in the development of CT-derived FFR (FFR-CT), which harnesses supercomputing power and complex mathematical modeling to calculate fluid pressure throughout the entire coronary artery tree, using valid fluid mechanics assumptions and 3-dimensional coronary and heart muscle anatomy generated by standard CTA. When normalized against a reference pressure, the result is a map of calculated FFR-CT throughout the entire coronary artery tree (see Figures 2 and 3). Importantly, FFR-CT requires nothing beyond good quality coronary CTA images. Pioneering researchers first introduced the concept of FFR-CT in 2009. The presentation was met with both strong skepticism and great excitement. Relying on mathematical generation of dynamic flow information from still images felt like a leap of faith. On the other hand, if CTA can simultaneously identify coronary artery ob-

(continued on p. 10)

At Oklahoma Heart Institute, we have chosen to become the first cardiology service in Oklahoma to provide FFR-CT for patient care.

(continued from p. 9)

struction and mark the ones likely to cause hypoperfusion (see Figure 4), then cardiologists can effectively limit use of invasive angiography after CTA, saving healthcare resources and reducing morbidity due to associated procedural complications.

In 2011, the DISCOVER-FLOW trial in 103 patients showed that FFR-CT dramatically improved specificity of predicting abnormal invasive FFR compared to CTA alone (82% compared to 25%).[6] Skepticism returned, however, as the much larger multicenter DeFACTO study in 2012 failed to show similar improvement.[7] Deflating results from the DeFACTO trial prompted renewed efforts in optimizing algorithms for simulating coronary arterial flow and tracing coronary artery anatomy. In 2014, the multicenter NXT trial, similar to DeFACTO in size with 254 patients, unequivocally showed improved specificity in predicting abnormal invasive FFR on a per-patient basis (84% compared to 32%) and per-artery basis (86% compared to 60%).[8] As expected, the benefit of adding FFR-CT was mostly driven by figuring out which intermediate coronary artery obstruction did not cause hypoperfusion. NXT results led the FDA to announce approval of FFR-CT (performed by Heartflow, Redwood City, California) for clinical use on November 26, 2014.

Subsequent to NXT and FDA approval, focus on FFR-CT has shifted to medical resource conservation and comparative performance. The PLATFORM study, which took 380 patients for whom invasive coronary angiography was planned and randomized them to usual care or FFR-CT guided care, published its results in 2015. Use of FFR-CT led to cancellation of invasive angiography in 61% of patients, a much lower rate of finding nonobstructive coronary arteries on invasive angiography (12% compared to 73%), and lower overall cost of care, without compromising safety.[9] Ongoing trials are examining how well adding FFR-CT to CTA directs judicious use of invasive angiography and comparing patient outcomes when CAD evaluation is done by FFR-CT or state-of the-art stress testing.

At Oklahoma Heart Institute, we believe the value of FFR-CT to noninvasively determine hemodynamically significance of obstructive CAD will only increase as efficiency of medical testing has become paramount. Therefore, we have chosen to become the first cardiology service in Oklahoma to provide FFR-CT for patient care, beginning in May of 2017. Our initial use of FFR-CT will focus on its main strength: resolving whether intermediately obstructive CAD causes hypoperfusion. FFR-CT ushers in an era when a single noninvasive test produces complimentary, detailed anatomic and dynamic flow information of the coronary arteries, and we are optimistic it will substantially elevate our overall testing approach for coronary artery disease.

Dr. Cheng is Director of the Cardiac Computed Tomography Department at Oklahoma Heart Institute and Hillcrest Medical Center. He is a specialist in noninvasive heart and vascular imaging, particularly in cardiac computed tomography (CT), a topic on which he has published numerous original research publications addressing quality, clinical use, and novel applications.

Figure 4

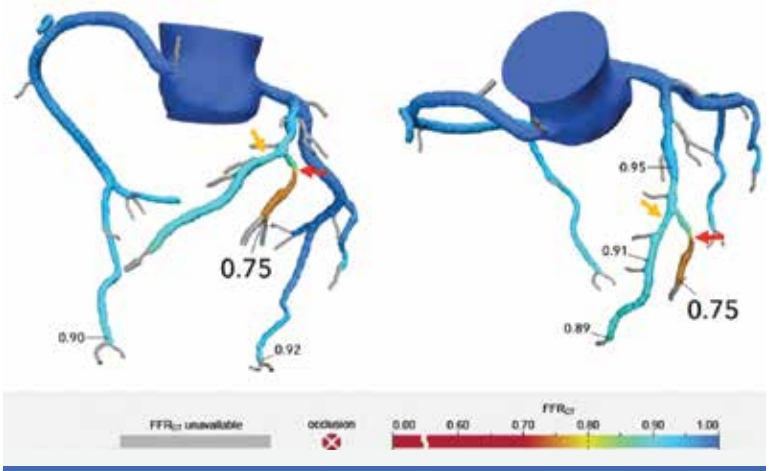

FFR-CT map in a patient with 50-69% diameter obstructive disease in the left anterior descending artery (orange arrows) and 70-80% diameter obstructive disease in the second diagonal artery (red arrows). FFR-CT calculations show coronary artery hypoperfusion in the second diagonal artery (value drops to 0.75) but not in the left anterior descending artery (values stay > 0.80 distal to the disease).

REFERENCES

1. Tonino PA, et al. Fractional flow reserve versus angiography for guiding percutaneous coronary intervention. N Eng J Med. 2009;360:213-224.
2. De Bruyne B, et al. Fractional flow reserve-guided PCI versus medical therapy in stable coronary disease. N Eng J Med. 2012;367:991-1001.
3. Meijboom WB, et al. Comprehensive assessment of coronary artery stenoses: computed tomography coronary angiography versus conventional coronary angiography and correlation with fractional flowreserve in patients with stable angina. J Am Coll Cardiol. 2008;52:636-643.
4. Linde JJ, et al. Long-term clinical impact of coronary CT angiography in patients with recent acute-onset chest pain: The Randomized Controlled CATCH Trial. JACC Cardiovasc Imaging.2015;8:1404–1413.
5. McKavanagh P, et al. A comparison of cardiac computerized tomography and exercise stress electrocardiogram test for the investigation of stable chest pain: the clinical results of the CAPP randomized prospective trial. Eur Heart J Cardiovasc Imaging. 2015;16:441–448.
6. Koo BK, et al. Diagnosis of ischemia-causing coronary stenoses by noninvasviev fractional flow reserve computed form coronary computed tomographic angiograms. Results from the prostpective multicenter DISCOVER-FLOW (Diagnosis of Ischemia-Causing Stenoses Obtained Via Noninvasive Fractional Flow Reserve) study. J Am Coll Cardiol. 2011;58:1989-1997.
7. Min JK, et al. Diagnostic accuracy of fractional fow reserve from anatomic CT angiography. JAMA. 2012;308:1237-1245.
8. Norgaard BL, et al. Diagnostic performance of noninvasive fractional flow reserve derived from coronary computed tomography angiography in suspected coronary artery disease: the NXT trial (Analysis of Coronary Blood Flow Using CT Angiography: Next Steps). J Am Coll Cardiol. 2014;63:1145-1155.
9. Douglas PS, et al. Clinical outcomes of fractional flow reserve by computed tomographic angiography-guided diagnostic strategies vs. usual care in patients with suspected coroanry artery disease: the prospective longitudinal trail of FFR(CT): outcome and resource impacts study. Eur Heart J. 2015;36:3335-3367.

Oklahoma Heart Institute

SERVICES

www.oklahomaheart.com

Interventional Cardiology
- Cardiac Catheterization
- Coronary Angioplasty
- Coronary Stents
- Multivessel Angioplasty and Stenting
- Atherectomy
- Rotablator Atherectomy
- Thrombolytic Therapy
- Carotid Stenting
- Fractional Flow Reserve
- Intravascular Ultrasound
- Intracardiac Echo
- Paravalvular Leak Plugs
- Myocardial Biopsy
- Pericardiocentesis
- Peripheral Angioplasty
- Peripheral Stents
- Percutaneous ASD Closures
- Percutaneous PFO Closures
- Impella Circulatory Support
- Therapeutic Hypothermia for Cardiac Arrest Patients
- Transcatheter Aortic Valve Replacement (TAVR)
- Transcatheter Mirtral Valve Repair
- Venous Ablation
- Aspiration Venous Thrombolic Obstructive Disease

Noninvasive Cardiology
- CT Angiography
- CT Heart Scan
- Cardiac and Vascular Screening Services
- Nuclear Cardiology
- Echo and Doppler Studies
- Nuclear and Echocardiographic Exercise and Pharmacological Stress Testing
- Retinal Imaging
- Thyroid Ultrasound
- Transesophageal Echocardiography, Arterial Venous Peripheral Vascular Imaging and Doppler Studies
- Peripheral Arterial Doppler and Duplex Imaging
- Cardiovascular Magnetic Resonance Imaging
- External Counterpulsation (ECP) Therapy
- Transcranial Doppler
- Aquapheresis Therapy

Electrophysiology
- Electrophysiology Studies
- Ablation Therapy
- Pacemaker Implantation
- Pacemaker and Lead Extraction
- Pacemaker Programming
- Pacemaker Monitoring and Clinic
- Implantable Cardioverter Defibrillator (ICD) Replacement
- ICD and Hardware Removal
- ICD Programming
- ICD Monitoring and Clinic
- Holter Monitoring and Interpretation
- 30 Day Cardiac Event Monitors
- Implantation and Interpretation of Long-Term Heart Monitors
- Signal Averaged EKGs and Interpretation
- Head Up Tilt Testing and Interpretation
- Direct Current Cardioversion
- Antiarrhythmic Drug Loading and Monitoring

Metabolic Disorders
- Diabetes
- Thyroid
- Hypertension
- Other Endocrine Problems

Specialty Clinics
- Advanced Center for Atrial Fibrillation
- Dysrhythmia and Pacer Clinic
- Hypertension Clinic
- Resistant Hypertension Clinic
- Adolescent and Adult Congenital Heart Clinic
- Lipid and Wellness Clinic
- Heart Failure Clinic
- Same Day Appointment Clinic
- Pre-Operative Clinic
- Center for the Treatment of Venous Disease
- Sleep Care
- Center for Peripheral Arterial Disease
- The Valve Clinic

Cardiovascular Surgery

CARDIAC SURGERY
- Coronary Artery Bypass
- Surgical Aortic Valve Replacement
- Transcatheter Aortic Valve Replacement with TAVR Team
- Mitral and Tricuspid Valve Repair and Replacement
- Surgical Treatment of Atrial Fibrillation: “Mini-Maze”, Full Maze, Left Atrial Appendage Ligation
- Cardiac Tumor Resection

THORACIC NON-CARDIAC SURGERY
- VATS (Video Assisted Thoracoscopy Surgery) for Biopsy and Treatment
- Minimally Invasive and Open Techniques for Diagnosis and Staging of Lung and Nonpulmonary Cancer in the Chest
- Minimally Invasive and Open Techniques for Therapeutic Lung Cancer Resection
- Surgical Treatment of Esophageal Cancer and Benign Esophageal Conditions

VASCULAR SURGERY
- Endovascular and Open Treatment of Aortic Aneurysms: Abdominal and Thoracic Diagnosis, Surgical, Interventional and Medical Management of Peripheral Arterial Disease (PAD)
- Surgical Treatment of Carotid Occlusive Disease
- Limb Salvage

MEDIASTINAL SURGERY
- Evaluation and Treatment of Mediastinal Masses

THYROID/ENDOCRINE SURGERY
- Full Spectrum of Thyroid Surgery (Total versus Near Total Thyroidectomy)
- Parathyroid Surgery with Intraoperative PTH monitoring
- Recurrent Nerve Monitoring

Oklahoma Heart Institute Hospital
1120 Utica Avenue
Tulsa, OK 74104
P) 918.574.9000

Oklahoma Heart Institute at Utica Physicians Offices
1265 S. Utica Avenue
Tulsa, OK 74104
P) 918.592.0999 • F) 918.595.0208

Oklahoma Heart Institute at Southpointe Physicians Offices
9228 S. Mingo Road
Tulsa, OK 74133
P) 918.592.0999 • F) 918.878.2408

Oklahoma Heart Institute At Hillcrest Hospital South
8801 S. 101st E. Avenue
Tulsa, OK 74133
P) 918.592.0999

THE DOCTORS OF OKLAHOMA HEART INSTITUTE

Wayne N. Leimbach, Jr., MD, FACC, FACP, FSCAI, FCCP, FAHA

Dr. Leimbach is a specialist in interventional and structural cardiology, including cardiac catheterization, coronary angioplasty, stents, atherectomy, laser, intravascular ultrasound imaging, and direct PTCA/stents for acute myocardial infarction. He also specializes in percutaneous closure of PFOs, ASDs, PDAs and percutaneous valve replacement or repair procedures such as TAVR and MitraClip. He is Director of the Cardiac and Interventional Laboratories at Oklahoma Heart Institute Hospital and also is Past Chief of Cardiology. Dr. Leimbach is Co-Founder of the Lipid and Wellness Clinic at Oklahoma Heart Institute. He is Director of the James D. Harvey Center for Cardiovascular Research at Hillcrest Medical Center, as well as Director of the Oklahoma Heart Research and Education Foundation. He also serves as Clinical Associate Professor of Medicine at the University of Oklahoma College of Medicine-Tulsa. Dr. Leimbach completed a Clinical Cardiology Fellowship and a Research Fellowship at the University of Iowa Hospitals and Clinics. He also completed his Internal Medicine Internship and Residency Programs at Iowa, where he was selected Chief Resident in Medicine. He received his medical degree from Northwestern University in Chicago and his Bachelor of Science degree from the University of Michigan.

Board certified in Internal Medicine, Cardiovascular Disease and Interventional Cardiology

Robert C. Sonnenschein, MD, FACC, ASE, RVT, RPVI

Dr. Sonnenschein specializes in echocardiography and noninvasive peripheral vascular imaging. He is Director of Echocardiography at Hillcrest Hospital South and past Director of Peripheral Vascular Ultrasound Imaging at Hillcrest Medical Center and Oklahoma Heart Institute and serves as Clinical Associate Professor of Medicine at the University of Oklahoma College of Medicine – Tulsa. He completed his Cardiology Fellowship at the State University of New York Upstate Medical Center in Syracuse, where he also completed his Internal Medicine Internship and Residency programs. Dr. Sonnenschein received his medical degree from Rush Medical College in Chicago and his Bachelor of Arts degree from the University of Pennsylvania.

Board certified in Internal Medicine, Cardiovascular Disease, and Adult Echocardiography Registered Vascular Technologist

James J. Nemec, MD, FACC

Dr. Nemec is a specialist in echocardiography, stress echocardiography and nuclear cardiology. He serves as Director of Nuclear Cardiology for Oklahoma Heart Institute. Dr. Nemec has served as Assistant Professor of Internal Medicine, Division of Cardiology, at Creighton University and as Assistant Professor, Department of Radiology, also at Creighton University. He completed his Clinical Cardiology Fellowship at the Cleveland Clinic Foundation and his Internal Medicine Internship and Residency at Creighton University. Dr. Nemec also completed a year of training in pathology at the University of Missouri, Columbia, MO. He received his medical degree from Creighton University, where he also received his Bachelor of Arts degree.

Board certified in Internal Medicine, Cardiovascular Disease and Nuclear Cardiology

Gregory D. Johnsen, MD, FACC, FSCAI

Dr. Johnsen is an interventional cardiologist with expertise in cardiac catheterization, angioplasty and related interventional procedures, such as stents and atherectomy. He is Director of Cardiac Rehabilitation at Hillcrest Medical Center and Director of the Hillcrest Exercise and Lifestyle Programs. He completed his Clinical Cardiology Fellowship at the University of Oklahoma – Oklahoma City, where he then finished an extra year of dedicated training in interventional cardiology. He completed his Internal Medicine Internship and Residency training at the University of Oklahoma – Oklahoma City, where he also received his medical degree. Dr. Johnsen received his Bachelor of Science degree from Oklahoma State University.

Board certified in Internal Medicine, Cardiovascular Disease and Interventional Cardiology

Alan M. Kaneshige, MD, FACC, FASE, RPVI

Dr. Kaneshige is a noninvasive cardiologist with expertise in adult echocardiography, stress echocardiography and transesophageal echocardiography. He is Director of Congestive Heart Failure at Oklahoma Heart Institute and Past Chief of Cardiology at Hillcrest Medical Center. Dr. Kaneshige completed his Internal Medicine Internship and Residency at Creighton University School of Medicine, where he also received his medical degree. He received a Bachelor of Science in chemistry at Creighton University. Dr. Kaneshige completed his Clinical Cardiology fellowship at Creighton, where he also served as Chief Cardiology Fellow for two years. He completed an additional Cardiac Ultrasound Fellowship at the Mayo Clinic in Rochester. Dr. Kaneshige served as Assistant Professor of Medicine at Creighton University School of Medicine, where he was Director of the noninvasive Cardiovascular Imaging and Hemodynamic Laboratory.

Board certified in Internal Medicine, Cardiovascular Disease, Adult and Transesophogeal Echocardiography

Edward T. Martin, MS, MD, FACC, FACP, FAHA

Dr. Martin is a noninvasive cardiologist with subspecialty expertise in noninvasive imaging. He is Director of Cardiovascular Magnetic Resonance Imaging at Oklahoma Heart Institute and Hillcrest Medical Center. In addition, he is a Clinical Associate Professor of Medicine at the University of Oklahoma College of Medicine – Tulsa. Dr. Martin has specialty training in Nuclear Medicine, as well as additional training dedicated to Cardiovascular Magnetic Resonance Imaging. He completed his Cardiology Fellowship at the University of Alabama and Internal Medicine Internship/Residency training at Temple University Hospital in Philadelphia. He received his medical degree from the Medical College of Ohio. Dr. Martin completed his Master of Science degree in mechanical engineering at the University of Cincinnati and his Bachelor of Science degree in physics at Xavier University. Dr. Martin is a founding member of the Society of Cardiovascular Magnetic Resonance and is a past editorial board member of the Journal of Cardiovascular Magnetic Resonance. Dr. Martin has also been actively involved with the American College of Cardiology (ACC) on a national level participating on numerous committees, writing groups and leadership positions. He is the current ACC Governor of the State of Oklahoma. He is also a 2 time past President of the Board of Directors of Tulsa Metropolitan Division of the American Heart Association and past President of the Intersocietal Commission for the Accreditation of Magnetic Resonance Laboratories (ICAMRL). Locally, he is the current Director of Cardiovascular MRI at OHI and the current Vice Chief of Staff at Hillcrest Hospital South.

Board certified in Internal Medicine and Cardiovascular Disease

Roger D. Des Prez, MD, FACC

Dr. Des Prez is a noninvasive cardiologist with specialty expertise in echocardiography, nuclear cardiology and cardiac computed tomography. He is Director of Cardiac Computed Tomography Services of the Cardiology Department at Bailey Medical Center. Dr. Des Prez received his medical degree and Bachelor of Arts degree from Vanderbilt University. He completed his Residency in Internal Medicine and Pediatrics at University Hospital of Cleveland. Dr. Des Prez practiced for six years as an internist with the Indian Health Services in Gallup, NM. He returned to Vanderbilt University as a member of the Internal Medicine Faculty, at which time he also completed his cardiology training.

Board certified in Internal Medicine, Cardiovascular Disease, Echocardiography, Pediatrics and Nuclear Cardiology

Christian S. Hanson, DO, FACE

Dr. Hanson is a specialist in Endocrinology, Metabolism and Hypertension at Oklahoma Heart Institute with expertise in diabetes, lipids and hypertension. He also serves as Clinical Associate Professor of Medicine in the College of Osteopathic Medicine – Oklahoma State University. He completed a Fellowship in Endocrinology, Metabolism and Hypertension at the University of Oklahoma in Oklahoma City. Dr. Hanson's Internal Medicine Residency and Rotating Internship were completed at Tulsa Regional Medical Center. He received his medical degree from Oklahoma State University and his Bachelor of Science degree from Northeastern Oklahoma State University in Tahlequah.

Board certified in Internal Medicine, Endocrinology and Metabolic Diseases

David A. Sandler, MD, FACC, FHRS

Dr. Sandler is a cardiologist with subspecialty expertise in electrophysiology, complex ablation, and atrial fibrillation management. Dr. Sandler is Director of Electrophysiology at Oklahoma Heart Institute Hospital. He completed his Cardiac Electrophysiology Fellowship and his Cardiovascular Medicine Fellowship at New York University Medical Center, New York, NY. Dr. Sandler performed his Internal Medicine Internship and Residency at Mount Sinai Medical Center, New York, NY. He earned his medical degree from Georgetown University School of Medicine in Washington, DC. Dr. Sandler received his Bachelor of Arts degree at the University of Pennsylvania in Philadelphia.

Board certified in Internal Medicine, Cardiovascular Disease and Cardiac Electrophysiology

Raj H. Chandwaney, MD, FACC, FSCAI, FSVM

Dr. Chandwaney is an interventional cardiologist with expertise in cardiac catheterization, coronary angioplasty and related interventional procedures such as coronary stents, atherectomy, intravascular ultrasound and peripheral vascular interventional procedures. Dr. Chandwaney is Chief of Cardiology and Director of the Chest Pain Center and Cardiology Telemetry Unit at Oklahoma Heart Institute Hospital. He completed his Clinical Cardiology Fellowship at Northwestern University Medical School in Chicago, IL., where he also completed an Interventional Cardiology Fellowship. Dr. Chandwaney's Internal Medicine Internship and Residency were performed at Baylor College of Medicine in Houston, TX. He received his medical degree from the University of Illinois at Chicago. Dr. Chandwaney completed his Master of Science degree at the University of Illinois at Urbana-Champaign, where he also received his Bachelor of Science degree.

Board certified in Internal Medicine, Cardiovascular Disease, Interventional Cardiology and Endovascular Medicine

D. Erik Aspenson, MD, FACE, FACP

Dr. Aspenson is a subspecialist in Endocrinology, Metabolism and Hypertension at Oklahoma Heart Institute, with expertise in diabetes, lipids, hypertension and thyroid diseases. He completed a fellowship in Endocrinology at Wilford Hall Medical Center, Lackland AFB, Texas. Dr. Aspenson's Internal Medicine Internship and Residency were completed at David Grant Medical Center, Travis AFB, California where he served as Chief Resident. He received his medical degree from the University of Oklahoma and his Bachelor of Science degree at Oklahoma State University.

Board certified in Internal Medicine, Endocrinology and Metabolic Diseases

Frank J. Gaffney, MD, FACC

Dr. Gaffney is an interventional and noninvasive cardiologist with subspecialty expertise in transesophageal echocardiography, nuclear cardiology, and coronary angiography. Dr. Gaffney is Director of Cardiology at Bailey Medical Center. He completed his Cardiovascular Medicine Fellowship at Scott & White Memorial Hospital in Temple, Texas. Dr. Gaffney completed his Internal Medicine Internship and Residency at Brooke Army Medical Center in San Antonio. He then remained on staff at Scott & White Memorial Hospital for several years, before entering his Fellowship in Cardiovascular Medicine. Dr. Gaffney earned his medical degree from New York Medical College, Valhalla, New York, and he received his Bachelor of Arts degree at Hofstra University in Hempstead, New York.

Board certified in Internal Medicine, Cardiovascular Disease and Nuclear Cardiology

Eric G. Auerbach, MD, FACC

Dr. Auerbach is a general cardiologist whose major interest is preventive cardiology and cardiovascular risk reduction. He completed his Cardiology Fellowship at the University of Miami/Jackson Memorial Hospital in Miami, FL, following which he obtained additional subspecialty training in cardiovascular MRI, nuclear cardiology, and cardiac CT imaging. His areas of expertise also include echocardiography, stress testing and management of lipid disorders. In addition to holding board certification in cardiovascular disease, he is a diplomat of the American Board of Clinical Lipidology. Dr. Auerbach's Internal Medicine Internship and Residency were performed at the University of Miami/Jackson Memorial Hospital. He earned

his medical degree at the University of Miami, Miami, FL, and his Bachelor of Arts degree at Princeton University, Princeton, NJ. Dr. Auerbach is the Director of Preventive Cardiology at Oklahoma Heart Institute, the medical director of The Weight Loss & Wellness Center at Oklahoma Heart Institute and a Clinical Associate Professor of Medicine at the University of Oklahoma College of Medicine – Tulsa.
Board certified in Internal Medicine, Cardiovascular Disease and Nuclear Cardiology

Robert L. Smith, Jr., MSc, MD, FACC, FSCAI

Dr. Smith specializes in interventional cardiology including cardiac catheterization, coronary angioplasty, and related interventional procedures such as coronary stents, atherectomy, intravascular ultrasound, and peripheral vascular interventional procedures. Dr. Smith is Director of Cardiology and the Cardiac and Interventional Laboratories at Hillcrest Hospital South. He completed an Interventional Cardiology Fellowship at the University of Florida College of Medicine in Jacksonville, FL. Dr. Smith performed his Clinical Cardiology Fellowship at Vanderbilt University School of Medicine in Nashville, TN and Tulane University School of Medicine in New Orleans. He received his medical degree from the University of Oklahoma College of Medicine in Oklahoma City and then completed his Internal Medicine Internship and Residency at Emory University School of Medicine in Atlanta, GA. Dr. Smith received his Bachelor of Arts, Bachelor of Science and Master of Science degrees at the University of Oklahoma in Norman, OK.
Board certified in Internal Medicine, Cardiovascular Disease, Interventional Cardiology and Nuclear Cardiology

Craig S. Cameron, MD, FACC, FHRS

Dr. Cameron is a specialist in cardiac electrophysiology, including catheter ablation of arrhythmias, atrial fibrillation management, pacemakers, implantable defibrillators, and cardiac resynchronization devices. Dr. Cameron is Director of Electrophysiology at Hillcrest Hospital South. He completed his Cardiac Electrophysiology Fellowship and his Cardiovascular Disease Fellowship at Baylor University Medical Center in Dallas, TX. Dr. Cameron's Internship and Internal Medicine Residency were performed at Baylor College of Medicine in Houston. He earned his medical degree from the University of Kansas School of Medicine in Kansas City, KS. Dr. Cameron received his Bachelor of Science degree at Pittsburg State University in Pittsburg, KS.
Board certified in Cardiovascular Disease and Cardiac Electrophysiology

Eugene J. Ichinose, MD, FACC

Dr. Ichinose specializes in interventional cardiology including cardiac catheterization, coronary angioplasty and related interventional procedures such as coronary stents, atherectomy, intravascular ultrasound and peripheral vascular interventional procedures. Dr. Ichinose is Director of Vein Services at Hillcrest Medical Center. He completed his Interventional and Clinical Cardiology Fellowships and his Internal Medicine Residency at the University of Massachusetts Memorial Health Care Center in Worcester, MA. Dr. Ichinose received his medical degree from Louisiana State University in New Orleans. He earned his Bachelor of Science degree from Texas Christian University in Fort Worth, TX.
Board certified in Internal Medicine, Cardiovascular Disease, Interventional Cardiology and Nuclear Cardiology

Cristin M. Bruns, MD

Dr. Bruns is a specialist in Endocrinology, Diabetes and Metabolism at Oklahoma Heart Institute, with expertise in diabetes, thyroid disease (including thyroid cancer) and polycystic ovary syndrome. She completed her Internal Medicine Internship and Residency and Endocrinology Fellowship at the University of Wisconsin Hospital and Clinics in Madison, WI. Dr. Bruns earned her medical degree from Saint Louis University School of Medicine in St. Louis, MO and her Bachelor of Arts and Bachelor of Science degrees in biology from Truman State University in Kirksville, MO. Prior to joining Oklahoma Heart Institute, Dr. Bruns worked as a clinical endocrinologist at the Dean Clinic in Madison, Wisconsin.
Board certified in Internal Medicine, Endocrinology and Metabolic Diseases

John S. Tulloch, MD

Dr. Tulloch is a noninvasive cardiologist with expertise in adult echocardiography, peripheral vascular imaging, nuclear cardiology, cardiac computed tomography and MRI. Dr. Tulloch is Director of the Cardiac and Vascular Ultrasound Department of Oklahoma Heart Institute/Hillcrest Medical Center's Cardiovascular Diagnostics. He completed his Cardiovascular Fellowship at the University of Kansas Medical Center in Kansas City, KS. Dr. Tulloch's Internal Medicine Internship and Residency also were completed at the University of Kansas Medical Center. He earned his medical degree from Ross University School of Medicine in New Brunswick, NJ and received his Bachelor of Science degree in biology from Avila University in Kansas City, MO.
Board certified in Internal Medicine, Cardiovascular Disease, Cardiovascular Tomography, and Nuclear Cardiology

Anthony W. Haney, MD, FACC

Dr. Haney is a noninvasive cardiologist with expertise in nuclear cardiology, echocardiography, peripheral vascular imaging and MRI. He also performs diagnostic cardiac catheterization. He completed his Cardiovascular Fellowship at the Medical College of Virginia in Richmond. Dr. Haney's Internal Medicine Internship and Residency were completed at the Mayo Clinic in Scottsdale, AZ. He earned his medical degree from the University of Oklahoma School of Medicine.
Board certified in Internal Medicine, Cardiovascular Disease and Nuclear Cardiology

Ralph J. Duda, Jr., MD, FACP, FACE, FASH, FNLA

Dr. Duda is a specialist in Endocrinology, Diabetes and Metabolism at Oklahoma Heart Institute, with expertise in diabetes, lipids, hypertension and thyroid diseases. Dr. Duda is Director of the Diabetes Education Center at Hillcrest Medical Center. He completed his Fellowship in Endocrinology and Metabolism at the Mayo Graduate School of Medicine, where he also completed his Residency in Internal Medicine. Dr. Duda received his medical degree from Northwestern University School of Medicine in Chicago, IL. He earned his Bachelor of Science degree from Benedictine University in Lisle, IL.
Board certified in Internal Medicine, Endocrinology, Diabetes and Metabolism, Clinical Lipidology, Clinical Hypertension, Clinical Bone Densitometry and Thyroid Ultrasonography

Douglas A. Davies, MD, FACC, FASNC

Dr. Davies is a hospital-based cardiologist who provides continuity of care for patients admitted to Oklahoma Heart Institute – Hospital. He completed a Clinical Cardiology Fellowship and additional training in nuclear cardiology at the Medical College of Virginia, where he also completed his Internal Medicine and Residency programs. Dr. Davies received his medical degree from Johns Hopkins University School of Medicine in Baltimore.
Board Certified in Internal Medicine, Cardiovascular Disease, Nuclear Cardiology and Cardiovascular Computed Tomography Angiography

Neil Agrawal, MD

Dr. Agrawal is a noninvasive cardiology specialist with expertise in adult echocardiography, nuclear cardiology, cardiac computed tomography and MRI. He completed his Cardiovascular Fellowship at the University of Vermont. Dr. Agrawal's Internal Medicine Internship and Residency were completed at the University of Louisville, and he earned his medical degree from St. George's University in Granada, West Indies. Dr. Agrawal completed his Bachelor of Science degree in biochemistry at the University of Texas at Austin.
Board certified in Internal Medicine

Kamran I. Muhammad, MD, FACC, FSCAI

Dr. Muhammad is a subspecialist in interventional cardiology. In addition to expertise in traditional areas of interventional cardiology, such as coronary intervention (angioplasty, stent placement, atherectomy, intravascular imaging) and peripheral vascular and carotid artery intervention, Dr. Muhammad has a special interest and expertise in interventional therapies for structural and valvular heart disease including the percutaneous non-surgical replacement and repair of heart valves — TAVR and MitraClip. As such, he currently serves as the Director of the Structural Heart Disease Program at OHI.

With dedicated and advanced training in structural heart disease intervention from the world-renowned Cleveland Clinic, Dr. Muhammad has been a pioneer in this field in Oklahoma. He led a team of OHI physicians in performing the first transcatheter aortic valve replacements (TAVR) and first transcatheter mitral valve repairs (MitraClip) in Tulsa and the region. Under his direction, these programs are the most experienced and comprehensive programs of their kind in the state, providing our patients with expert care and class-leading technologies for the non-surgical treatment of structural and valvular heart diseases.

In addition to his clinical experience, Dr. Muhammad has authored many peer-reviewed articles and textbook chapters on important cardiology topics. He also serves as Clinical Associate Professor of Medicine at the University of Oklahoma College of Medicine — Tulsa.

Dr. Muhammad completed his Clinical Cardiology and Interventional Cardiology Fellowships at the Cleveland Clinic which included additional dedicated training in peripheral vascular and structural cardiac intervention. Dr. Muhammad completed his Internal Medicine Internship and Residency at Yale University where he was selected and served as Chief Resident. He earned his medical degree from the University of Massachusetts Medical School, graduating with top honors and election to the Alpha Omega Alpha (AΩA) honor society. Dr. Muhammad earned his Bachelor of Science degree in computer science from the University of Massachusetts, Amherst.
Board certified in Internal Medicine, Cardiovascular Disease, Nuclear Cardiology and Interventional Cardiology

Arash Karnama, DO, FACC

Dr. Karnama is a specialist in interventional cardiology, including cardiac catheterization, coronary intervention, nuclear cardiology, echocardiography (TEE/TTE), cardioversion, peripheral angiography, peripheral intervention, carotid angiography, intravascular ultrasound, atherectomy, and PTCA/stenting for acute myocardial infarction. He is Director of the Cardiology Department at Hillcrest Hospital Claremore. Dr. Karnama completed his Interventional and Clinical Cardiology Fellowships at Oklahoma State University Medical Center and his Internal Medicine Internship and Residency at the Penn State Milton S. Hershey Medical Center in Hershey, PA. Dr. Karnama received his medical degree from Des Moines University in Des Moines, IA and his Bachelor of Arts degree from the University of Iowa in Iowa City.
Board certified in Internal Medicine, Interventional Cardiology, Cardiovascular Disease, Nuclear Cardiology, and Cardiovascular Computed Tomography

Victor Y. Cheng, MD, FACC, FSCCT

Dr. Cheng joins Oklahoma Heart Institute after serving as cardiology faculty at Cedars-Sinai Medical Center and assistant professor at the University of California in Los Angeles. Dr. Cheng is Director of the Cardiac Computed Tomography Department at Oklahoma Heart Institute and Hillcrest Medical Center. He is a specialist in noninvasive heart and vascular imaging, particularly in cardiac computed tomography (CT), a topic on which he has published numerous original research publications addressing quality, clinical use, and novel applications. Dr. Cheng's training includes a Clinical Cardiology Fellowship and Advanced Cardiac Imaging Fellowship at Cedars-Sinai Medical Center, and an Internal Medicine Internship and Residency at the University of California in San Francisco. Dr. Cheng received his medical degree from Northwestern University in Chicago, IL and his Bachelor of Science degree from Northwestern University in Evanston, IL.
Board certified in Internal Medicine, Cardiovascular Disease, Nuclear Cardiology, Echocardiography and Cardiovascular Computed Tomography

Jana R. Loveless, MD

Dr. Loveless is a sleep specialist, with expertise in the diagnosis and treatment of sleep disorders. She is Director of the Sleep Medicine Program at Hillcrest Hospital Claremore, Hillcrest Hospital Henryetta, and Hillcrest Hospital South. Prior to joining Oklahoma Heart Institute, Dr. Loveless was with Nocturna of Tulsa. She completed her Internal Medicine Residency program at the University of Oklahoma, Tulsa, where she was Chief Resident. She also earned her medical degree from, the University of Oklahoma, Tulsa. Dr. Loveless completed graduate studies at Texas Tech University, and she earned her Bachelor of Arts degree at Davidson College in Davidson, North Carolina.
Board Certified in Internal Medicine and Sleep Medicine

Mathew B. Good, DO, FACC, RPVI

Dr. Good is an invasive/noninvasive cardiology specialist with expertise in adult echocardiography, nuclear cardiology, cardiac computed tomography, peripheral vascular ultrasound and MRI. He completed his Cardiovascular Fellowship at the University of Kansas Medical Center in Kansas City, KS, where he also completed his Internal Medicine Internship and Residency. Dr. Good received his medical degree from the Oklahoma State University Center for Health and Sciences in Tulsa and his Bachelor of Arts degree from the University of Colorado in Boulder.
Board certified in Internal Medicine and Cardiovascular Computed Tomography

Stanley K. Zimmerman, MD, FACC, FSCAI

Dr. Zimmerman is the Director of the Catheterization Laboratory and Peripheral Vascular Services at Hillcrest Hospital South. He is the medical director of OHI vascular imaging laboratory. He is a specialist in interventional cardiology, including cardiac catheterization, coronary angioplasty, and related interventional procedures such as coronary stents, atherectomy, vascular ultrasound, and peripheral interventional procedures. Dr. Zimmerman specializes in complex vascular interventions, endo-

vascular repair of abdominal aortic aneurysms and complex aorto-iliac disease, treatment of critical limb ischemia, and vascular management of arterial and venous based wounds.

He completed his Interventional and Cardiovascular Fellowships at the University of Kansas Medical Center in Kansas City, KS, as well as his Internal Medicine Internship and Residency. In addition, Dr. Zimmerman received his medical degree from the University of Kansas Medical Center and his Bachelor of Arts degree from the University of Kansas in Lawrence.

Board certified in Internal Medicine, Cardiovascular Disease and Interventional Cardiology

Stephen C. Dobratz, MD, FACC

Dr. Dobratz specializes in diagnostic and interventional cardiology, including cardiac catheterization, peripheral angiography, pacemakers and defibrillators, cardioversion, cardiac nuclear studies, cardiac computed tomography, transesophageal echo and echocardiograms. Dr. Dobratz is Director of the Cardiac Catherization Laboratories at Hillcrest Hospital Claremore. He completed his Fellowship in Cardiology at Allegheny General Hospital in Pittsburgh, Pennsylvania. Dr. Dobratz completed his Internal Medicine Internship and Residency at the University of Arizona in Tucson. He earned his medical degree at Eastern Virginia Medical School in Norfolk and his undergraduate degree at James Madison University in Harrisonburg, Virginia.

Board certified in Cardiovascular Disease

Michael Phillips, MD, FACC, FACS

Dr. Phillips is a Cardiovascular Thoracic Surgeon at Oklahoma Heart Institute. He completed his fellowship at Mid America Heart Institute in Kansas City, MO and his general surgery residency at the Mayo Graduate School of Medicine. He earned his medical degree from the University of Missouri. Dr. Phillips received his undergraduate degrees in Biology and Chemistry at William Jewell College in Liberty, MO.

Board certified by in Thoracic and General Surgery

James B. Chapman, MD, FACC, FSCAI

Dr. Chapman is a specialist in interventional cardiology, including cardiac catheterization, coronary angioplasty and related interventional procedures such as stents, atherectomy, laser, intravascular ultrasound imaging and direct PTCA for acute myocardial infarction. He completed a Clinical Cardiology Fellowship at St. Vincent Hospital and Health Care Center in Indianapolis, IN. He also completed his Internal Medicine Internship and Residency programs at St. Vincent. Dr. Chapman received his medical degree from Indiana University School of Medicine in Indianapolis and his Bachelor of Science degree from Indiana University in Bloomington, IN.

Board certified in Internal Medicine, Cardiovascular Disease and Interventional Cardiology

Joseph J. Gard, MD, FACC, FHRS

Dr. Gard is a cardiologist who specializes in electrophysiology, complex ablation and atrial fibrillation management. He completed his Cardiac Electrophysiology Fellowship and his Cardiology Fellowship at the Mayo School of Graduate Medical Education in Rochester, Minnesota. Dr. Gard also performed his Internal Medicine Residency at Mayo. He earned his medical degree from the University of Nebraska in Omaha, Nebraska. Dr. Gard received his Bachelor of Science degree from Boston College in Chestnut Hill, Massachusetts.

Board certified in Cardiovascular Disease, Internal Medicine, Electrophysiology and Clinical Cardiac Electrophysiology

Edward J. Coleman, MD, FACC, FAHA, FACS, FCCP

Dr. Coleman is a cardiovascular surgeon who specializes in cardiac, thoracic and vascular surgery. He completed his residency in cardiothoracic surgery at State University of New York at Buffalo in Buffalo, New York. He was Senior & Chief Resident at Mary Imogene Bassett Hospital/Columbia University College of Physicians & Surgeons in Cooperstown, New York. Dr. Coleman performed his Internship and Residency in general surgery at the University of Rochester School of Medicine & Dentistry in Rochester, NY. He earned his medical degree from State University of New York at Buffalo School of Medicine, Buffalo, New York. Dr. Coleman received his Bachelor of Arts degree from Norwich University in Northfield, Vermont.

Board Certified in General Surgery and Thoracic Surgery

Michael B. Newnam, MD

Dr. Newnam is Director of Sleep Medicine at Hillcrest Medical Center and Hillcrest Hospital Cushing. He is a Board Certified specialist in the diagnosis and treatment of sleep disorders. He completed his Family Practice Internship & Residency programs at the Womack Army Medical Center in Ft. Bragg, NC. Dr. Newnam earned his medical degree from the University of Oklahoma and his Bachelor of Science degree from Oral Roberts University in Tulsa, OK.

Board Certified in Family Medicine and Sleep Medicine

John M. Weber, MD, RPVI

Dr. Weber is a Peripheral Vascular Surgeon at Oklahoma Heart Institute who specializes in complex vascular disease. He offers both open and endovascular treatment of arterial and venous disease. Areas of interest include open and endovascular treatment of aortic pathology, cerebrovascular surgery, limb salvage surgery, vascular access, and complex venous therapies. He completed his residency in Vascular Surgery at the Cleveland Clinic in Cleveland, Ohio. Dr. Weber earned his medical degree at the University of Oklahoma College of Medicine. He also completed his undergraduate degree at the University of Oklahoma.

David Liff, MD

Dr. Liff is an interventional cardiologist who specializes in peripheral vascular disease as well as coronary interventional disease. He completed a Peripheral Interventional Fellowship at Ochsner Clinic in New Orleans, LA. and an Interventional Cardiology Fellowship at Hofstra/North Shore University /Long Island Jewish Hospital Center in New York. Dr Liff completed his Clinical Cardiology Fellowship at Emory University Hospital System in Atlanta, GA. He also performed his Internal Medicine Internship and Residency at Emory. Dr. Liff earned his medical degree from Ohio State University School of Medicine. He received his Bachelor of Science degree from the University of Michigan in Ann Arbor, MI.

Board certified in Internal Medicine, Cardiovascular Disease and Interventional Cardiology

Saran Oliver, MD

Dr. Oliver is an invasive/noninvasive cardiology specialist with specific interests in adult echocardiography, nuclear cardiology, and women's cardiovascular health. She completed her Cardiovascular Fellowship at Scott and White Memorial Hospital in Temple, TX. Dr. Oliver performed her Internal Medicine Internship and Residency at the University of Texas Southwestern Medical Center in Dallas, TX. She also earned her medical degree from the University of Texas Southwestern Medical Center. Dr. Oliver attended Rice University in Houston, TX where she received her Bachelor of Arts degree in Sports Medicine.

Board certified in Internal Medicine, board eligible in Cardiovascular Medicine

Lauren LaBryer, MD

Dr. LaBryer is a specialist in Endocrinology, Metabolism and Hypertension at Oklahoma Heart Institute. She completed her Endocrinology Fellowship at the University of Oklahoma College of Medicine. She also completed her Internal Medicine Internship and Residency Programs at Oklahoma, where she was selected as Chief Resident in Medicine. In addition, Dr. LaBryer earned her medical degree from the University of Oklahoma College of Medicine. She received her Bachelor of Science degree in Biopsychology and Cognitive Sciences from the University of Michigan.

Board certified in Internal Medicine, and board eligible in Endocrinology and Metabolic Diseases

Jordan A. Brewster, MD

Dr. Brewster is a specialist in electrophysiology, with expertise in electrophysiology, complex ablation, and atrial fibrillation management. He completed his Fellowship in Electrophysiology at Indiana University in Indianapolis, IN. Dr. Brewster performed his Fellowship in Cardiovascular Disease at the University of Kentucky Division of Cardiovascular Medicine in Lexington, KY, where he was Chief Fellow. He completed his Internal Medicine Internship and Residency at Vanderbilt University in Nashville, TN. Dr. Brewster received his medical degree from the University of Virginia School of Medicine in Charlottesville, VA. and his Bachelor of Science degree in Biochemistry from the University of Oklahoma.

Board certified in Internal Medicine, Cardiovascular Disease and Nuclear Cardiology

Ahmad Iqbal, MD

Dr. Iqbal is an invasive/noninvasive cardiologist at Oklahoma Heart Institute who specializes in advanced heart failure patients, including those with left ventricular assist devices (LVAD) as well as patients with cardiac transplantation. His special interest is mechanical circulatory support options for patients requiring additional life support measures including ECMO, Impella, and LVADs. Dr. Iqbal also is a diplomate of the National Board of Echocardiography and specializes in adult comprehensive echocardiography, including stress echocardiography and transesophageal echocardiography. He also has an interest in nuclear and preventative cardiology. He completed his Advanced Heart Failure and Transplant Fellowship at Northwestern University Feinberg School of Medicine in Chicago, IL. Dr. Iqbal completed his Cardiovascular Disease Fellowship at Mid America Heart Institute at St. Luke's Hospital/University of Missouri-Kansas City, MO. Dr. Iqbal completed his Internal Medicine Residency at the University of Texas Southwestern in Dallas, TX. He received his medical degree from Tulane University School of Medicine and his Bachelor of Business Administration degree from Loyola University in New Orleans, LA, where he graduated summa cum laude.

Board certified in Internal Medicine, Cardiovascular Diseases, and Echocardiography. Board eligible in Nuclear Cardiology. Board eligible in Advanced Heart Failure and Transplant

Mrudula R. Munagala, MD, FACC

Dr. Munagala is Director of the Advanced Heart Failure program at Oklahoma Heart Institute. She specializes in Heart Failure, Mechanical Circulatory Support Devices (MCSD) and Transplant. Dr. Munagala is also experienced in managing patients with Pulmonary Hypertension and Cardiac Heart and Lung amyloidosis. She undertook advanced training in Heart Failure, MCSD and Transplant fellowship at UCLA-Ronald Reagan Medical Center in Los Angeles, CA after completing her Internal Medicine residency and Cardiovascular Diseases fellowship at Drexel University College of Medicine, Philadelphia, PA. She also completed a Heart Failure and Pulmonary Hypertension fellowship at Allegheny General Hospital, Pittsburgh, PA. Dr. Munagala received her medical degree from Sri Venkateswara Medical College in Andhra Pradesh, India. She has been involved in clinical research in Heart Failure, Ventricular Assist Devices (VAD) and Transplant and authored several articles and book chapters. She is an active member in various professional societies, including the American College of Cardiology, Heart Failure Society of America, International Society of Heart and Lung Transplant and American Medical Association.

Board Certified in Internal Medicine, Cardiovascular Diseases, Heart Failure and Transplant, Echocardiography and Nuclear Cardiology

Siva Soma, MD, FACC, FHRS

Dr. Soma is a specialist in electrophysiology, with expertise in complex catheter ablation of cardiac arrhythmias and management of atrial fibrillation, ventricular tachycardia, pacemakers, defibrillators and cardiac resynchronization devices. He completed his Fellowship in Electrophysiology at the University of Pittsburgh Medical Center in Pittsburgh, PA. Dr. Soma performed his Fellowships in Cardiovascular Disease and Advanced Heart Failure/Transplantation at Allegheny General Hospital in Pittsburgh. He completed his Internal Medicine Internship and Residency at Hahnemann University Hospital, Drexel University College of Medicine in Philadelphia, PA. Dr. Soma completed a Master's degree in public health and received his medical degree from Armed Forces Medical College in India.

Board certified in Internal Medicine, Cardiovascular Disease and Nuclear Cardiology

Who's Flying Your Plane?

The OHI Executive Health Program

By Frank J. Gaffney, MD

As a captain and physician in the United States Army, I've had the privilege of taking care of many deserving soldiers, retirees and their families. When I was assigned to Ft. Hood in Texas, we did a lot of routine physicals on the troops. I remember one group of soldiers quite well — pilots. When the helicopter pilots were evaluated, they underwent an extensive set of chest X-rays that were sent to Brooks Air Force base, where they were read by an old radiologist who had been there forever. In fact, he read X-rays on all the Air Force pilots too.

What were they looking for? Coronary Calcium. Turns out the military knew the importance of screening for coronary artery disease long before coronary calcium CT scanning became fashionable. Why did the military go to extra lengths to screen the pilots for CAD? Not only had they spent time and money training pilots to perform, they were flying equipment that was worth tens of millions of dollars! Making sure pilots and the equipment they were flying were safe was a high priority. Asymptomatic pilots who were found to have extensive coronary calcium underwent screening coronary angiograms, no questions asked.

Flash forward to my career here at Oklahoma Heart Institute. I've been lucky enough to be part of our OHI Executive Health Program. With the same concern that the military had for their pilots, we have designed our program to keep our executive patients safe. In the corporate world, the executives are the pilots of the company, managing complex multi-million dollar corporations.

Our comprehensive program comes with state of the art blood testing, vascular and cardiac ultrasound, coronary calcium CT scans, and stress testing with pulmonary function testing combined with max VO2, aerobic and anaerobic threshold determinations. Additionally, we can tailor other screenings that are important to the executive team to include dermatologic and cancer screening. We believe that our program rivals any program out there. More importantly, unlike other executive health programs that are designed as screening programs only, if significant issues are uncovered, patients have immediate access to the most comprehensive, state of the art cardiology group in the region.

Cardiovascular advancements have made it possible to uncover significant issues before they cause problems. With the help of the OHI Executive Health Program, let us keep your most valuable asset healthy.

Dr. Gaffney is an interventional and noninvasive cardiologist at OHI, with subspecialty expertise in transesophageal echocardiography, nuclear cardiology, and coronary angiography. He is Co-Director of the OHI Executive Health Program.

Introduction to the Hybrid Algorithm And the New Coronary CTO Vocabulary

By Raj H. Chandwaney, MD, FACC, FSCAI, FSVM

INTRODUCTION

Chronic total occlusion (CTO) is a term used to describe a coronary artery that is completely blocked for at least 3 months.[1] CTOs are very prevalent as they are documented in up to 20% of diagnostic angiograms.[2] Major coronary arteries with CTOs are sometimes supported via complex networks of collateral blood vessels from the remaining patent coronary arteries. Although arteries with a collateralized CTO are often receiving enough arterial blood flow via the collateral network to prevent complete infarction in the territory fed by the artery with the CTO, patients often experience exertional angina or dyspnea because the myocardium is still ischemic due to suboptimal arterial blood flow.

Percutaneous coronary intervention (PCI) of CTOs is very challenging. The initial step required during percutaneous coronary intervention involves advancing an intracoronary guidewire across the blockage. The guidewire provides a platform over which balloons, stents, and any other ancillary equipment can be safely advanced into the coronary artery to treat the blockage. During CTO PCI, this initial step is usually difficult and sometimes impossible to achieve. The CTO is often densely fibrotic and impassable. Additionally, it is sometimes difficult for the interventional cardiologist to understand which direction the guidewire should be directed because the distal coronary artery is not adequately visualized (due to the more proximal CTO preventing flow to the distal segments of the artery). Because of these challenges, percutaneous coronary interventions in CTOs are often regarded as the "final frontier" in the field of percutaneous coronary intervention. Recent advances such as the hybrid CTO algorithm have been developed to help interventional cardiologists conquer this "final frontier."

BENEFITS OF CTO PCI

Successful CTO PCI provides numerous benefits. These benefits are listed below and the scientific evidence that supports this list is summarized in the paragraphs that follow:

- Reducing anginal symptoms such as chest pain and/or dyspnea.
- Decrease the need for coronary artery bypass graft surgery.
- Decrease the need for anti-anginal medications.
- Reduce mortality (compared to patients with failed CTO PCI).
- Improve left ventricular function.
- Decrease the risk for arrhythmias.
- Improve tolerance to acute coronary syndromes that may occur in the future.

Successful CTO PCI can decrease or eliminate angina,[3,4] non-anginal symptoms,[5] and improve exercise capacity. [6] A large meta-analysis that compared patients in whom CTO PCI failed versus those in whom CTO PCI was successful demonstrated that a successful CTO PCI produced significant reductions in recurrent angina during 6 years of follow up.[4]

CTO PCI may reduce the need for patients to undergo coronary artery bypass graft surgery. In patients with stable coronary disease, the SYNTAX trial demonstrated coronary artery bypass graft surgery reduces mortality and the risk of myocardial infarction compared to PCI in patients with very complex disease (high SYNTAX scores), but outcomes are similar in patients with less complex disease (SYNTAX score < 23). Many patients decline coronary artery bypass graft surgery due to concerns regarding complications and recovery. Other patients are at increased risk for complications with coronary artery bypass graft surgery due to multiple medical comorbidities, age, and/or the need to undergo a redo coronary artery bypass graft surgery. CTO PCI provides additional treatment options for many of these patients. Additionally, CTO PCI is preferable to coronary artery bypass graft surgery in patients with single vessel disease involving a CTO who have refractory angina, and in patients with prior coronary artery bypass graft surgery who re-present with angina and are found to have a patent left internal mammary artery bypass graft to the left anterior descending coronary artery with an unprotected CTO due to failed saphenous vein bypass grafts.

Successful CTO PCI decreases the need for anti-anginal medications. Many patients prefer eliminating medications whenever possible to eliminate possible side effects and costs. Additionally, eliminating the chronic use of long acting nitrates enables many male patients to use phosphodiesterase inhibitors such as sildenafil, varenafil, or tadalifil to treat erectile dysfunction (a medical problem that has a high prevalence in male patients with coronary artery disease).

Whether or not CTO PCI improves survival is arguable. Many observational studies have shown better survival among patients with successful versus failed CTO PCI even though bare metal stents were used in many of those studies.[4, 8, 9] Another recently published large, multicenter analysis not only revealed that successful CTO PCI was associated with improved survival, it also revealed that the surivival benefit was present regardless of the vessel that was treated (left anterior descending, circumflex, and right coronary artery CTO PCI all provided mortality benefit).[10] Complete revascularization has been associated with lower risk for death, myocardial infarction, and revascularization compared to incomplete revascularization.[11] The presence of a CTO is strongly associated with incomplete revascularization,[12] which in turn is associated with an unfavorable outcome.[13,14] In another study of 301 patients who underwent myocardial perfusion imaging before and after CTO PCI, a baseline ischemic burden of greater than 12.5% was optimal in identifying patients most likely to have a significant decrease in ischemic burden post successful CTO PCI. Hence, the highest benefit of CTO PCI is most likely to be achieved in patients with significant baseline myocardial ischemia.[15] It should also be noted that a well-developed collateral circulation to the CTO target vessel does not necessarily suggest that ischemia is absent. When

Figure 1

The hybrid CTO algorithm

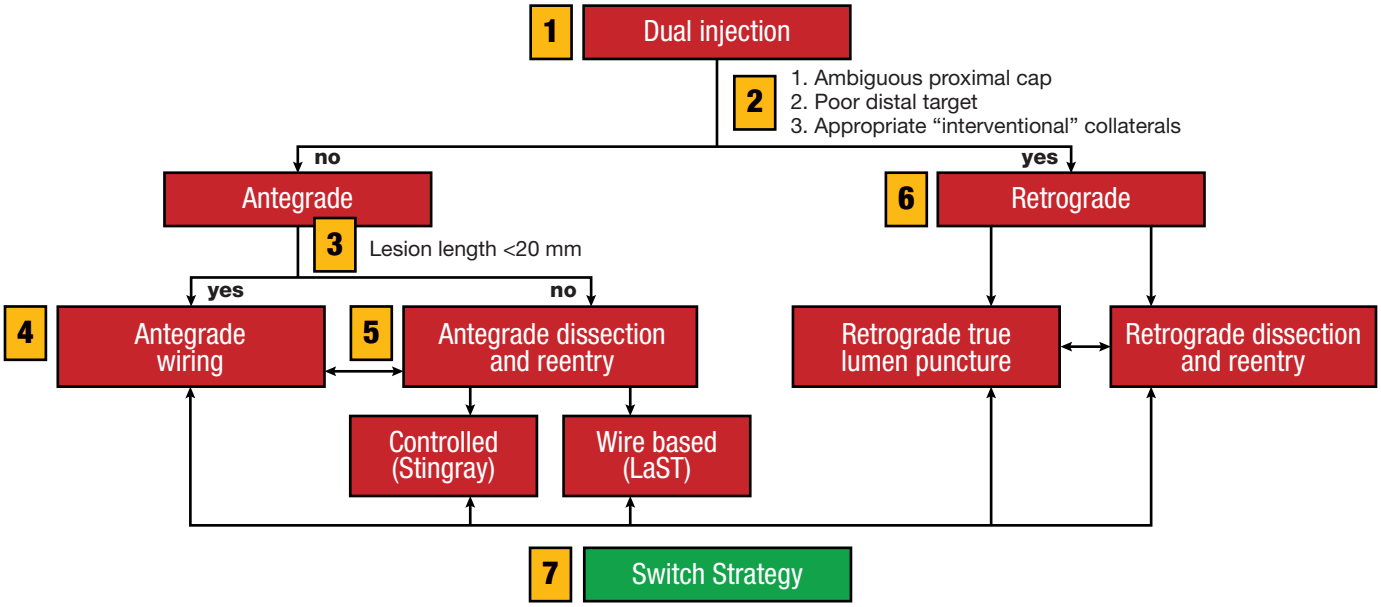

fractional flow reserve (FFR) was measured in 92 patients immediately after wire crossing, FFR was < .80 in all patients.[16] Similar findings were present in another study of 50 patients with CTO who were all found to demonstrate ischemia regardless of the presence of collateral circulation.[17]

Successful CTO PCI has been shown to improve left ventricular systolic function in numerous studies.[18-26] Improvement of left ventricular systolic function is only expected to occur if the CTO supplied myocardium is viable,[23,26] and the vessel remains patent during follow-up.[21,22]

It has been hypothesized that CTO PCI may reduce the risk for life threatening arrhythmias. Ischemia may predispose to ventricular arrhythmias. Among 162 patients with ischemic cardiomyopathy who received an implantable cardiac defibrillator, 44% had at least one CTO.[27] During a median follow-up of 26 months, the presence of CTO was associated with higher rates of ventricular arrhythmias and death.[27] Currently, there are no prospective studies demonstrating that CTO PCI decreases the risk for ventricular arrhythmias, but this is likely to be an area of future research.

Experts also propose that successful CTO PCI may improve a patient's tolerance for future acute coronary syndrome.[1] Patients with a CTO who develop an acute coronary syndrome have much worse outcomes than those who do not have a CTO (including patients with multivessel coronary artery disease).[28-31] Although there are no prospective studies demonstrating that prophylactic CTO PCI can improve the outcomes of future acute coronary syndrome, a retrospective study showed improved long-term outcomes in patients with successful CTO PCI versus those with failed CTO PCI after presenting for primary PCI due to acute ST elevation myocardial infarction.[32]

THE HYBRID ALGORITHM

The challenges associated with coronary CTO percutaneous coronary intervention have traditionally resulted in a more conservative strategy regarding their management. In patients with multivessel coronary artery disease who are found to have a coronary CTO, the presence of the CTO is often the primary factor that leads to referral for coronary artery bypass surgery. In patients with single vessel coronary artery disease found to have a coronary CTO, percutaneous coronary intervention attempts have typically been reserved for those patients who demonstrate severe angina despite optimized medical therapy. Recently developed advances with the hybrid algorithm suggest that the historic paradigm used to refer patients with coronary CTO for PCI needs modification.

The optimal approach to CTO PCI continues to evolve. In January 2011, several high-volume CTO operators met in Bellingham, Washington and created a consensus algorithmic approach to CTO PCI.[33] This approach was named the "hybrid algorithm" (Figure 1). It integrates all possible wire crossing strategies (antegrade wire escalation, antegrade dissection/reentry, and retrograde). The algorithm directs physicians to the safest, most effective, and most efficient strategy based on the anatomy of the CTO. A fundamental principle of the hybrid algorithm requires that operators master all the skill sets of CTO PCI and be able to alternate between these techniques during the same CTO PCI procedure in order to recanalize the CTO.[1]

The first and most important step of the hybrid approach to CTO PCI is to perform simultaneous dual guide catheter coronary angiography. Dual guide catheter angiography allows complete anatomic assessment of the CTO. The hybrid algrorithm requires operators to assess four anatomic characteristics of the CTO:

- Clear or ambiguous proximal cap anatomy
- Lesion length (< or > 20 mm length)
- Quality of the distal target
- Presence or absence of "interventional" collaterals

By incorporating these four anatomic characteristics of the CTO, the hybrid algorithm directs the operator to the best initial crossing strategy and also provides guidance for subsequent strategies that may be utilized if the initial strategy is not successful. For example, a CTO with a clearly defined (tapered) proximal cap, 15 mm length, good distal target, and absent "interventional" collaterals (too small or tortuous for retrograde crossing) is best approached with an initial strategy involving antegrade wire escalation, and a secondary strategy involving antegrade dissection/reentry. On the other hand, a CTO with an ambiguous proximal cap, 25 mm length, poor distal target, and good "interventional" collaterals is best approached with an initial retrograde dissection/reentry strategy.

Alternating between different CTO strategies is at the heart of the hybrid algorithm.[1] Should one approach fail, another approach should be utilized.

(continued on p. 18)

Figure 2A

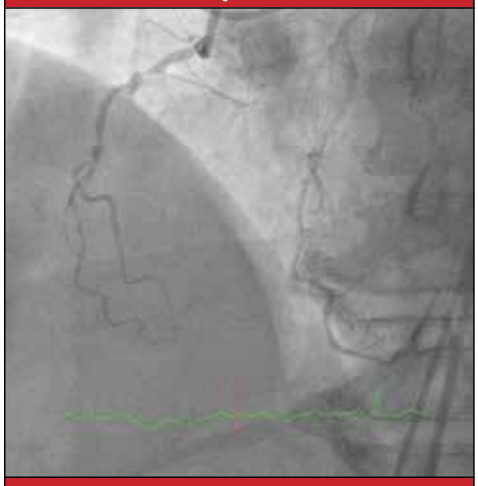

A recent CTO case successfully completed using the hybrid algorithm at the Oklahoma Heart Institute. Baseline angiogram of the right coronary artery reveals a CTO.

Figure 2B

Initial efforts using antegrade wire escalation resulted in the wire entering a side branch (red arrow). The proximal cap anatomy was discovered to be more ambiguous than anticipated.

Figure 2C

After the initial antegrade strategy failed, the septal collaterals were mapped with a left coronary angiogram to attempt a retrograde strategy.

Figure 2D

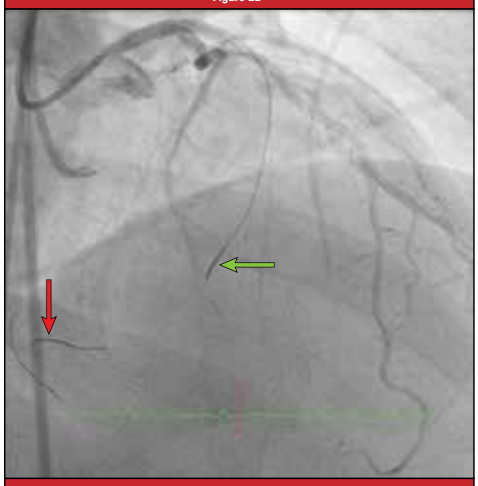

The septal collaterals were successfully crossed with a wire (red arrow) but the retrograde support catheter (green arrow) could not be advanced through the septal collaterals.

Figure 2E

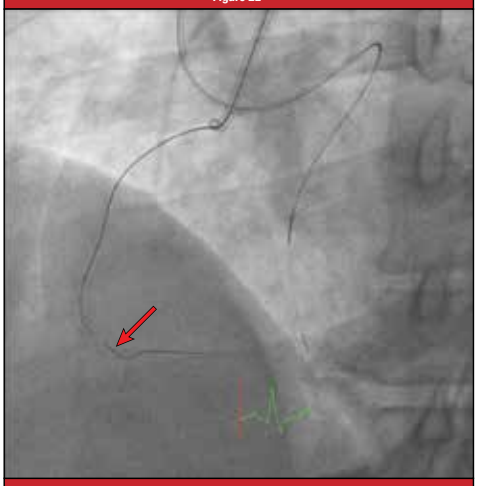

The antegrade wire escalation strategy was attempted again with the retrograde wire (red arrow) used as a "just marker" wire to overcome the anatomic ambiguity.

Figure 2F

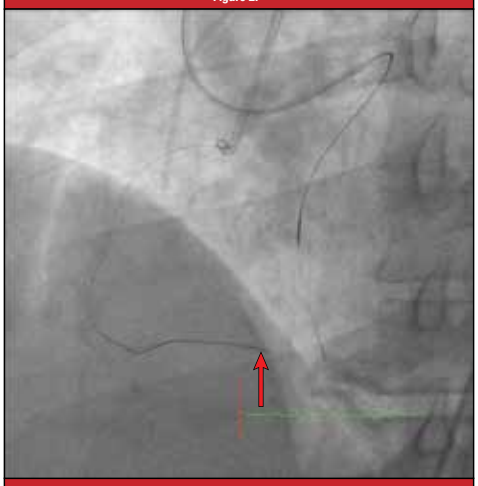

Antegrade wire tip successfully advanced across the CTO (red arrow).

Figure 2G

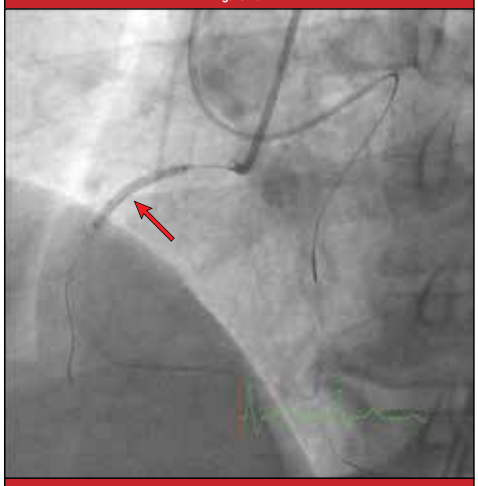

Due to difficulties advancing a balloon catheter across the CTO, a "stent anchor" (red arrow) was deployed across a second wire to maximize guide support and allow completion of the CTO PCI.

Figure 2H

An excellent final result was achieved. This case illustrates how the hybrid algorithm integrates multiple strategies to ultimately achieve a successful outcome for the patient.

(continued from p. 17)

Every CTO case is unique and may require a different set of strategies for success. A recent CTO case successfully completed using the hybrid algorithm at the Oklahoma Heart Institute is presented (see figures 2A-H). This case illustrates how the hybrid algorithm integrates multiple strategies to ultimately achieve a successful outcome for the patient.

IMPACT OF THE HYBRID CTO ALGORITHM

The hybrid CTO algorithm has made a major impact on the dissemination and application of CTO PCI techniques in recent years.[1] An initial single operator experience with the hybrid CTO algorithm was presented at a professional meeting in 2013 and reported a procedural success rate of 90.4% during 73 consecutive PCI cases.[34] This success rate was much better than the previously expected success rate for CTO PCI that had historically approximated 75%.[35] Shortly thereafter, a "hybrid registry" of 144 cases performed by five different centers was presented at a CTO summit meeting and reported a procedural success rate of 94% using the hybrid algorithm.[36] Recently, several publications in peer reviewed medical journals confirm overall procedural success rates that exceed 90% with low complication rates using the hybrid CTO algorithm.[37-39] The CTO PCI procedural

success rates reported in the studies utilizing the hybrid CTO alogorithm seem to far exceed those reported during the same era performed without the hybrid algorithm.[40]

THE NEW CTO VOCABULARY

The advent of the hybrid CTO algorithm has led to the development of a plethora of new acronyms and terms to describe the various approaches and techniques that are used during CTO PCI cases. The following glossary of the new CTO vocabulary is provided to aid the reader in gaining a greater appreciation of the terms that may be used to summarize the details of a CTO procedure by the operator during a verbal discussion or within a procedural report.

Antegrade wire escalation — Antegrade approach used to cross short CTOs within the true lumen of the vessel. The hybrid algorithm suggests using only three possible wires (Fielder XT, Pilot 200, or Confianza Pro 12) with this approach to minimize the required inventory.

Antegrade dissection/reentry — Antegrade approach with which the subintimal space is intentionally entered to advance equipment around the CTO. This technique has emerged as the safest and most efficient approach for crossing long (>20 mm) CTOs. This technique takes advantage of the distensibility of the subintimal space. In the past, distal true lumen re-entry was challenging, but the development for dedicated equipment has facilitated this approach.

Retrograde approach — CTO is approached from the distal vessel by advancing a guidewire against the direction of blood flow. Guidewire is advanced into the artery distal to the occlusion through either a bypass graft or a collateral channel.

Base of operations — Location of active effort during the course of a CTO PCI procedure (proximal cap, within the CTO, distal cap, etc.)

Knuckle wire — A technique that involves advancing a prolapsed wire through the subintimal space. Blunt dissection through the subintimal space with a knuckle wire is believed to be safer than sharp dissection with the tip of a CTO wire.

Crossboss catheter — A catheter specially designed for CTO PCI that has a blunt 1 mm hydrophilic tip that is used to safely advance past a CTO in the subintimal space (see figure 3). The catheter is rotated rapidly using the "fast spin" technique.

Stingray balloon/guidewire — A system that was specifically designed to re-enter into the true lumen of the vessel after advancing past the CTO in the subintimal space (see figure 4).

Subintimal Tracking And Reentry (STAR)- The original antegrade dissection reentry technique described by Dr. Antonio Colombo. The subintimal space is crossed using a knuckled wire that is advanced as distally as necessary until it spontaneously re-enters into the distal true lumen.

Limited Antegrade Subintimal Tracking (LAST or mini-STAR) — Similar to STAR but the operator attempts to re-enter into the true lumen just distal to the CTO using a stiff guidewire with a 90 degree bend.

Contrast Guided STAR (Carlino Technique) — Subintimal contrast injection via a microcatheter in-

(continued on p. 20)

Figure 3

The CrossBoss catheter

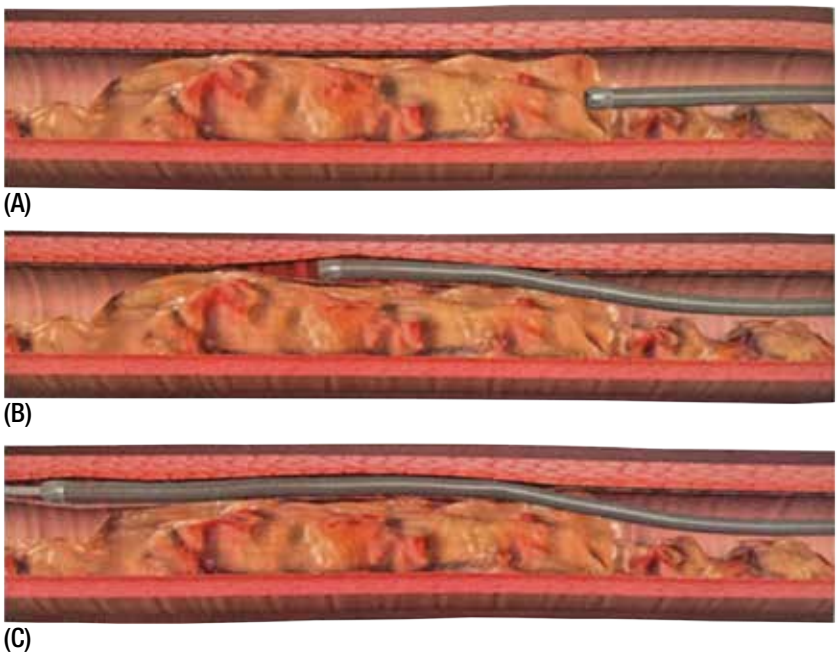

A catheter specially designed for CTO PCI that has a blunt 1 mm hydrophilic tip that is used to safely advance past a CTO in the subintimal space.

Figure 4

The Stingray balloon and guidewire

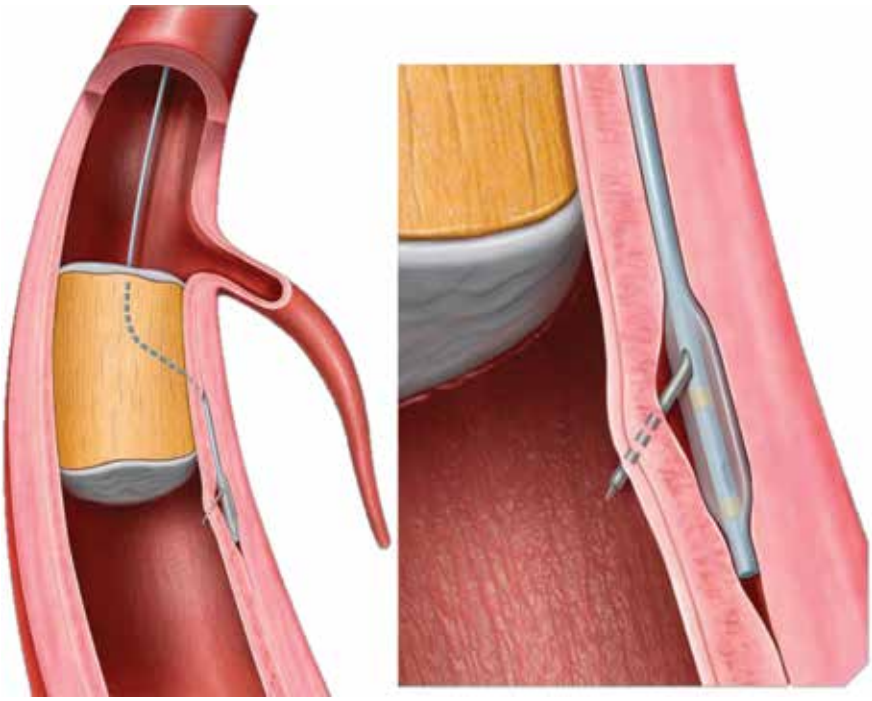

A system that was specifically designed to reenter into the true lumen of the vessel after advancing past the CTO in the subintimal space.

(continued from p. 19)

serted into the proximal cap to create and visualize a dissection plane around the CTO that may facilitate guidewire advancement.

Scratch and Go — Antegrade technique used to enter the subintimal space in cases with proximal cap ambiguity. The technique incorporates a stiff guidewire directed towards the wall proximal to the ambiguous cap. A microcatheter is then advanced into the subintimal space and the stiff wire is exchanged for a hydrophillic knuckle wire that is advanced in the subintimal space distal to the CTO.

Balloon Assisted Subintimal Entry (BASE) — Inflating an oversized balloon proximal to a CTO with proximal cap ambiguity to create a dissection and facilitate insertion of a wire into the subintimal space.

Balloon Assisted Microdissection (BAM or grenadoplasty) — Inflating an undersized balloon within a balloon uncrossable CTO until it intentionally ruptures to create a dissection plane that might facilitate advancement of a balloon further through the CTO.

Anchor balloon - A workhorse guidewire is advanced into a small proximal side branch followed by a balloon that is inflated to anchor the guide, and facilitate the delivery of balloons or microcatheters across a previously uncrossable CTO.

Stent anchor — A second wire is intentionally stented up against the wall proximal to the CTO to anchor the guide catheter, and facilitate the delivery of balloons, or microcatheters across a previously uncrossable CTO.

Stick and drive — Conventional technique used to re-enter into the true lumen using the Stingray balloon. An initial puncture is performed into the true lumen using the Stingray wire; after confirmation of the wire in the true lumen using a contralateral contrast injection, the wire is rotated 180 degrees and advanced.

Stick and swap — After puncture into the true lumen using the Stingray wire, the wire is swapped out for a hydrophyllic wire (Pilot 200) which is advanced through the "tunnel" created by the Stingray wire into the distal vessel to minimize any dissection that may be caused by the stiff tipped Stingray wire.

Subintimal TRAnscatheter Withdrawal (STRAW) — Aspiration of a subintimal hematoma that can develop during antegrade/dissection re-entry. The technique can be performed through the Stingray balloon or through another microcatheter placed adjacent to the Stingray balloon catheter in the subintimal space.

Bobsled technique — Attempting re-entry more distally after Stingray re-entry failure by advancing the Stingray balloon more distally to an area that may be less densely calicified.

Septal surfing — A technique used to cross septal collaterals which may or may not be angiographically obvious using a soft tipped wire (Sion or Fielder FC) with a microcatheter (Corsair or Turnpike).

Controlled antegrade and retrograde tracking and dissection (CART) — A technique for reentry into the true lumen after subintimal CTO crossing via the retrograde approach. A balloon is inflated over the retrograde guidewire creating a space into which an antegrade guidewire is advanced.

Reverse CART — The opposite of CART. A balloon is inflated over the antegrade guidewire instead of the retrograde guidewire (more commonly used during coronary CTO PCI; see figure 5).

Stent reverse CART — A stent is deployed proximally to facilitate retrograde wiring into the stent.

Wire externalization — After a retrograde wire crosses the CTO and is in the true proximal lumen, it is advanced into the antegrade guide followed by a retrograde microcatheter so that it can be exchanged for a longer wire (R350 or RG3). The longer retrograde wire is advanced until it exits the antegrade guide proximal hub so it can be secured. This step allows PCI to be performed antegrade, over the retrograde wire.

Trapping — Inflating a balloon in the antegrade guide adjacent to a wire to fix the wire in place while moving equipment over that wire. The technique is used to fix the retrograde wire in place in the antegrade guide and facilitate advancement of the retrograde microcatheter into the antegrade guide. Many CTO operators now use the technique to pin the antegrade wire during all over the wire equipment exchanges to reduce flouroscopy times.

Ping pong technique — Alternating engagement of the target vessel with two guide catheters. When utililizing the retrograde approach to cross a CTO via an ipsilateral collateral, a second ipsilateral guide is beneficial for trapping and externalizing the guidewire, because if the retrograde wire is inserted into the antegrade guide catheter, equipment delivery would be more difficult through the same guide catheter.

"Just marker" technique — A retrograde wire is advanced to the distal cap and act as a marker within the distal true lumen to act as a target for the antegrade wire. The technique can be especially useful in patients with renal insufficiency whose anatomy is favorable for anterior wire escalation or antegrade dissection and re-entry approaches.

Dancing wires — An observation that antegrade and retrograde wires move synchronously in the same direction when they are both travelling along the course of the CTO. In contrast, if one wire has exited the course of the CTO, the wires will move asynchronously in different directions.

Kissing wires — Manipulation of both antegrade and retrograde wires in the CTO until the wires meet. The antegrade wire is then advanced through the channel created by the retrograde wire into the true distal lumen.

Figure 5

Reverse CART

(controlled antegrade and retrograde tracking and dissection)

A technique for reentry into the true lumen after subintimal CTO crossing via the retrograde approach. A balloon is inflated over the antegrade guidewire creating a space into which a retrograde guidewire is advanced.

CONCLUSION

Coronary CTOs have a high prevalence amongst patients with coronary artery disease. Successful CTO PCI may have numerous benefits such as reducing angina symptoms, decreasing the need for angina medications, reducing the need for coronary artery bypass graft surgery, improving systolic function, and possibly reducing mortality. The hybrid CTO algorithm integrates antegrade and retrograde CTO techniques to optimize patient safety and improve procedural success rates during CTO PCI. Recently published data appear to confirm that the hybrid CTO algorithm will continue to improve the outcomes for patients with coronary artery disease who have a CTO that may have previously been declared irreparable. The highly skilled physicians at Oklahoma Heart Institute will continue to monitor and master this rapidly evolving area of cardiology so that we may continue to offer our patients the most progressive treatments available.

Dr. Chandwaney is an interventional cardiologist with expertise in cardiac catheterization, coronary angioplasty and related interventional procedures such as coronary stents, atherectomy, intravascular ultrasound and peripheral vascular interventional procedures. Dr. Chandwaney is Chief of Cardiology and Director of the Chest Pain Center and Cardiology Telemetry Unit at Oklahoma Heart Institute Hospital.

REFERENCES:

1. Brilakis ES. Manual of Coronary Chronic Total Occlusion Interventions: A Step-By-Step Approach. 2014.
2. Zidar FJ, Kaplan BM, O'Neill WW, et al. Prospective, randomized trial of prolonged intracoronary urokinase infusion for chronic total occlusions in native coronary arteries. J Am CollCardiol. 1996;27(6):1406-1412.
3. Grantham JA, Jones PG, Cannon L, Spertus JA. Quantifying the early health status benefits of successful chronic total occlusion recanalization: results from the Flowcardia's approach to chronic total occlusion recanalization (FACTOR) trial. CircCardiovascQual Outcomes. 2010; 3: 284-90.
4. Joyal D, Afilalo J, Rinfret S. Effectiveness of recanalization of chronic total occlusions: asystematic review and meta-analysis. Am Heart J. 2010; 160: 179-87.
5. Safley DM, Grantham J, Jones PG. Spertus J. Health status benefits of angioplasty for chronic total occlusions-an analysis from the OPS/PRISM studies. J Am CollCardiol. 2012; 59: E101.
6. Olivari Z, Rubartelli P, Piscione F, et al. Immediate results an one year clinical outcomes after percutaneous coronary interventions in chronic total occlusions. Data from a multicenter, prospective, observational study (TOAST-GISE). J Am CollCardiol. 2003; 41: 1672-8.
7. Mohr FW, Morice MC, Kappetein AP, et al. Coronary artery bypass graft surgery versus percutaneous coronary intervention in patients with three vessel disease and left main coronary disease: 5 year follow-up of the randomized clinical SYNTAX trial. Lancet. 2013; 381: 629-38.
8. Khan MF, Wendel CS, Thai HM, Movahed MR. Effectsof percutaneous revascularization of chronic total occlusions on clinical outcomes: a meta-analysis comparing successful versus failed percutaneous intervention for chronic total occlusion. Catheter CardiovascInterv. 2013; 82: 95-107.
9. Muramatsu T. Hiranom K. Tsukahara R. et al. Long-term outcome of percutaneous transluminal coronary intervention for chronic total occlusion in the BMS era in Japan. CardioascIntervTher. 2010; 25: 78-84.
10. George S, Cockburn J, Clayton TC, et al. Long-Term Follow-Up of Elective Chronic Total Coronary Occlusion Angioplasty: Analysis From the U.K. Central Cardiac Audit Database. J Am CollCardiol. 2014; 64(3):235-243.
11. Garcia S, Sandoval Y, Roukoz H, et al. Outcomes after complete versus incomplete revascularization of patients with multivessel coronary artery disease: a meta-analysis of 89,883 patients enrolled in randomized clinical trials and observational studies. J Am CollCardiol. 2013.
12. Farooq V, Serruys PW, Garcia-Garcia HM, et al. The negative impace of incomplete angiographic revascularization on clinical outcomes and its association total occlusions: the SYNTAX trial. J Am CollCardiol. 2013; 61: 282-94.
13. Hannan EL, Wu C, Walford G, etal. Incomplete revascularization in the era of drug eluting stents: impact on adverse outcomes. JACC CardiovascInterv. 2009; 2: 17-25.
14. Genereux P, Palmerini T, Caixeta A, et al. Quantification and impact of untreated coronary artery disease after percutaneous coronary intervention: the residual SYNTAX score. J Am CollCardiol. 2012; 59: 2165-74.
15. Safley DM Koshy S, Grantham JA, et al. Changes in myocardial ischemic burden following percutaneous coronary interventions of chronic total occlusions. Catheter CardiovascInterv. 2011; 78: 337-43.
16. Werner GS, Surber R. Ferrari M, Fritzenwanger M, Figulla HR. The functional reserve of collateral supplying long-term cronic total coronary occlusions in patients without prior myocardial infarction. Eur Heart J. 2006; 27: 2406-12.
17. Sachdeva R, Agrawal M, Flynn SE, Swerner GS, Uretsky BF. The myocardium supplied by a chronic total occlusion is a persistently ischemic zone. Catheter CardiovascInterv. 2013.
18. Melchior JP, Doriot PA, Chatelain P, et al. Improvement of left ventricular contraction and relaxation synchronism after recanalization of chronic total coronary occlusion by angioplasty. J Am CollCardiol. 1987; 9: 763-8.
19. Danchin N, Angioi M, Cador R, et al. Effect of late percutaneous angioplasic recanalization of total coronary artery occlusion on left ventricular remodeling, ejection fraction, and regional wall motion. Am J Cardiol. 1996; 78: 729-35.
20. Van Belle E, Blouard Pm McFadden EP, Lablanche JM, Bauters C, Bertrand ME. Effects of stenting of recent of chronic coronary occlusions on late vessel patency and left venricular function. Am J Cardiol 1997; 80: 1150-4.
21. Sirnes PA, Myreng Y, Molstad P, Bonarjee V, Golf S. Improvement in left ventricular ejection fraction and wall motion after successful recanalization of chronic coronary occlusions. Eur Heart J. 1998; 19:273-81.
22. Piscione F, Galasso G, De Luca G, et al. Late reopening of an occluded infarct related artery improves left ventricular function and long term clinical outcome. Heart. 2005; 91: 646-51.
23. Baks T, van Geuns RJ, Duncker DJ, et al. Prediction of left ventricular function after drug eluting stent implantation for chronic total coronary occlusions. J Am CollCardiol. 2006; 47: 721-5.
24. Kirschbaum SW, Baks T, van den Ent M, et al. Evaluation of left ventricular fucnction three years after percutaneous recanalization of chronic total coronary occlusions. Am J Cardiol. 2008: 101: 179-85.
25. Cheng AS, Selvanayagam JB, Jerosch-Herold M, et al. Percutaneous treatment of chronic total coronary occlusions improves regional hyperemic myocardial blood flow and contractility: insights from quantitative cardiovascular magnetic resonance imaging. JACC CardiovascINterv. 2008; 1: 44-53.
26. Werner GS, Surber R, Kuethe F, etal. Collaterals and the recovery of left ventricular function after recanalization of a chronic total coronary occlusion. Am Heart J. 2005; 149: 129-37.
27. Nombela-Franco L, Mitroi CD, Fernandez-Lozano I, et al. Ventricular arrhythmias among implantable cardioverter-defibrillator recipients for primary prevention: impact of chronic total coronary occlusion (VACTO Primary Study). CircArrhythmElectrophysiol. 2012; 5: 147-54.
28. Claessen BE, Dangas GD, Weisz G, et al. Prognostic impact of a chronic total occlusion in a non-infarct related artery in patients with ST segment elevation myocardial infarction: 3 year results from the HORIZONS-AMI trial. Eur Heart J. 2012; 33: 768-75.
29. Claessen BE, van der Schaaf RJ, Verouden NJ, et al. Evaluation of the effect of a concurrent chronic total occlusion on long-term mortality and left ventricular function in patients after primary percutaneous coronary intervention. JACC CardiovascInterv. 2009; 2: 1128-34.
30. Hoebers LP, Vis MM, Claessen BE, et al. The impact of multivessel disease with and without a co-existing chronic total occlusion on short and long term mortality in ST-elevation myocardial infarction patients with and without cardiogenic shock. Eur J Heart Fail. 2013; 15: 425-32.
31. Lexis CP, van der Horst IC, Rahel BM, et al. Impact of chronic total occlusions on markers of reperfusion, infarct size, and long-term mortality:; a substudyofrom the TAPAS- trial. Catheter CardiovascInterv. 2011; 77: 484-91.
32. Yang ZK, Zhang RY, Hu J, Zhang Q, et al. Impact of successful staged revascularization of a chronic total occlusion in the non infarct related artery on long-term outcome in patients with acut ST segment elevation myocardial infarction. Int J Cardiol. 2013; 165: 76-79.
33. Brilakis ES, Grantham JA, Rinfret S, et al. A percutaneous treatment algorithm for crossing coronary chronic total occlusions. JACC CardiovascInterv. 2012; 5: 367-79.
34. Society of Cardiac Angiographers and Interventionalists 2013 Annual Meeting. Orlando, FL.
35. Patel VG, Brayton KM, Tamayo A, et al. Angiographic success and procedural complications in patients undergoing percutaneous coronary chronic total occlusion interventions: a weighted meta-analysis of 18,061 patients from 65 studies. JACC CardiovascInterv. 2013;6(2):128-36.
36. Daniels D. 2012 CTO Summit. New York, NY.
37. Christopoulos G, Menon RV, Karmpaliotis D, et al. The efficacy and safety of the "hybrid" approach to coronary chronic total occlusions: insights from a contemporary multicenter US registry and comparison with prior studies. J Invasive Cardiol. 2014;26(9):427-32.
38. Christopoulos G, Karmpaliotis D, Alaswad K, et al. The efficacy of "hybrid" percutaneous coronary intervention in chronic total occlusions caused by in-stent restenosis: insights from a US multicenter registry.Catheter CardiovascInterv. 2014 Oct 1;84(4):646-51.
39. Christopoulos G, Menon RV, Karmpaliotis D, Alaswad K, et al.Application of the "hybrid approach" to chronic total occlusions in patients with previous coronary artery bypass graft surgery (from a Contemporary Multicenter US registry). Am J Cardiol. 2014 Jun 15;113(12):1990-4.
40. Bittl JA. Percutaneous Coronary Intervention for Chronic Total Occlusions: The Power of Negative Thinking. J Am CollCardiolIntv. 2015;8(2): 245-253.

SKILLET SKIRT STEAK FAJITAS WITH JICAMA SALSA Serves 4

Sweet, crisp jicama makes a terrific fresh salsa for sizzling hot skirt steak and vegetables. Other good accompaniments to this classic Texas meal include guacamole or sliced avocado and sour cream.

3/4 cup peeled, grated jicama

1 small tomato, diced

1 jalapeño pepper, seeded and diced

1/4 cup chopped fresh cilantro

Juice of 1 lime

3/4 teaspoon fine sea salt, divided

1 1/4 pound skirt steak, cut into 2 or 3 pieces to fit in your skillet

1 1/4 teaspoon chili powder

4 teaspoons expeller-pressed canola oil, divided

1 large onion, halved and cut into thick slices

2 bell peppers, cut into strips

4 cloves garlic, sliced

8 whole grain tortillas, warmed

Combine jicama, tomato, jalapeño, cilantro, lime juice and 1/4 teaspoon salt in a small bowl. Set aside.

Sprinkle steak with chili powder and remaining 1/2 teaspoon salt. Heat a large cast-iron skillet over high heat. When very hot, but not smoking, add 2 teaspoons canola oil and then the steak. Cook until well browned, 2 to 3 minutes per side. Transfer to a cutting board and set aside. Return the skillet to high heat and add remaining 2 teaspoons canola oil, onion, bell peppers and garlic. Cook, stirring, 2 minutes. Lower heat to medium, cover skillet, and cook, stirring occasionally, until vegetables are tender, about 8 minutes.

Slice steak thinly against the grain. Remove the skillet from the heat, push vegetables to one side, and place steak slices on other side. Pass jicama salsa and warm tortillas and let guests roll the steak and vegetables in the tortillas and top with salsa.

KALE, CARROT AND AVOCADO SALAD

Serves 4

If you're in an Eating Clean state of mind, this one's just for you. Delicious and quick to prep,

Whole Foods' simple salad sings with avocado, providing rich flavor and creamy texture. Honestly, so delicious! Why not give it a whirl?

1 bunch kale, stemmed and finely chopped

2 cups grated carrots

1/2 avocado, peeled and pitted

1/4 cup thinly sliced red onion

2 tablespoons lemon or lime juice

2 tablespoons sesame seeds, toasted

1/2 teaspoon reduced sodium soy sauce

Toss all ingredients together in a large bowl. Use your hands or the back of a large spoon to thoroughly mash avocado into kale. Set aside at room temperature for 30 minutes before serving to allow kale to soften.

CREAMY CUCUMBER DIP

Makes about 2 cups

This easy and refreshing dip, featuring cashews for creaminess, is best enjoyed the day it's made. Serve with fresh vegetables or spread on toasted whole grain bread. Super satisfying!

1 1/2 cup raw cashews

1 English cucumber, peeled and shredded

2 tablespoons fresh lemon juice

1/4 cup freshly chopped dill

2 tablespoons freshly chopped chives

2 tablespoons toasted pine nuts

Soak cashews with enough water to cover for at least 4 hours. Drain.

Place shredded cucumber in a strainer and set aside for at least 15 minutes to drain, then squeeze out as much excess liquid as possible. You should have about 1 1/2 cups packed shredded cucumber. Transfer cucumber to the bowl of a food processor. Add drained cashews, lemon juice, dill and chives and purée until dip is smooth and creamy. Garnish with pine nuts and serve.

Oklahoma Heart Institute

Screening Tests That Can Save Your Life and Prevent Heart Attack and Stroke

No physician referral required.
Open to the general public.
Evening appointments available.

Call today for your appointment!

918.592.0999

Exclusively at Oklahoma Heart Institute

The Cardiovascular Screening Program is provided by Oklahoma Heart Institute, a trusted name in Northeast Oklahoma for more than 20 years.

918.592.0999 • 1265 South Utica Ave • 9228 South Mingo
www.OklahomaHeart.com

5 Easy Ways to Live Longer

According to the American Heart Association, many people experience no symptoms before having a heart attack or stroke.

A series of simple screening tests by trained experts in cardiovascular disease can identify problems before symptoms develop, preventing issues down the road. *The cost is low. The tests are simple and fast. Aren't you worth it?*

1 Carotid Artery Evaluation

Strokes rank 3rd among all causes of death behind diseases of the heart and cancer. To assess your risk for stroke, an ultrasound probe is placed on your neck to screen for blockages in your carotid arteries which supply blood to the brain. This is also a marker of heart attack risk. **15 minutes, $40**

2 Cardiac Function Evaluation

To analyze cardiac function and calculate your Ejection Fraction (the amount of blood your heart is able to pump), an ultrasound probe will be positioned at various locations on your chest. **15 minutes, $40**

3 Abdominal Aorta Evaluation

Most abdominal aneurysms are asymptomatic. They're the 10th leading cause of death in males over 55. To screen for aneurysm, an ultrasound probe is used to analyze your abdominal aorta. **15 minutes, $40**

4 Ankle/Brachial Index

Blood pressures are obtained from your legs and arms to screen for peripheral artery disease. It not only assesses circulation to the legs, but also is a marker of heart attack risk. **15 minutes, $40**

5 Cardiac Calcium Score

Coronary plaque can build up silently for years, and if untreated can cause blockages and heart attacks. This test measures the calcified plaque in the coronaries and is an indirect measure of the total amount of plaque in the coronaries. A multi-slice CT scanner takes a series of pictures of your heart in just a few seconds. **15 minutes, $99**

Living Longer Just Got Easier.

It's fast, accurate, painless and you don't need a physician's referral.

Combine Screenings and Save:
Schedule screenings 1 - 4 and receive a $20 discount.

OHI-FLY-1209-0011

OKLAHOMA HEART INSTITUTE
1265 S. Utica Avenue
Suite 300
Tulsa, OK 74104

Presorted Standard
U.S. Postage Paid
Tulsa, OK
Permit No. 2146

Through the Years

Heart disease strikes young and old alike, taking many shapes and forms.
At Oklahoma Heart Institute, our specialists treat heart problems that occur through all ages.
From a rhythm disturbance in young athletes, to heart attacks in the middle aged,
to valve replacement in the elderly, the doctors of OHI have the technology
and expertise to care for you all through your years.

For a continuum of heart care that stands the test of time, trust the doctors of
Oklahoma Heart Institute.

Oklahoma Heart Institute

Nationally Recognized Cardiovascular Specialists | **918.592.0999** | **www.oklahomaheart.com**

1120 SOUTH UTICA AVE. Oklahoma Heart Institute (The Heart Hospital) | 1265 SOUTH UTICA (Utica Physicians Office) | 9228 SOUTH MINGO (SouthPointe Physicians Office) | 8801 SOUTH 101ST E. AVE. (Hillcrest South)