# Oklahoma Heart Institute

VOLUME 11 | NUMBER 1 | SPRING 2016

## *The Vascular Center at Oklahoma Heart Institute*

Peripheral Arterial Disease and More Durable Results

Critical Limb Ischemia

Aorto-Iliac Occlusive Disease

Treatment for Venous Insufficiency & Ulceration

Whole Heart Healthy Foods for Spring

...and MORE!

Oklahoma Heart Institute

Oklahoma Heart Institute Hospital
1120 Utica Ave., Tulsa, OK 74104
P) 918.574.9000

Oklahoma Heart Institute
at Utica Physicians Offices
1265 S. Utica Ave., Suite 300, Tulsa, OK 74104
P) 918.592.0999 • F) 918.595.0208

Oklahoma Heart Institute
at Southpointe Physicians Offices
9228 S. Mingo Road, Suite 200, Tulsa, OK 74133
P) 918.592.0999 • F) 918.878.2408

Hillcrest Hospital South
8801 S. 101st E. Ave., Tulsa, OK 74133
P) 918.294.4000



*Published by Oklahoma Heart Institute*
*Edited by Newsgroup Communications, Tulsa, OK*
*Designed by Amanda Watkins*
*For advertising information contact:*
*Elaine Burkhardt at 918.749.2506*
*newsgroupcom@sbcglobal.net*
*visit our website at www.oklahomaheart.com*

*The Oklahoma Heart Institute Magazine is mailed directly to referring physicians and other referring health care professionals in the Tulsa area and is also available in our patient waiting rooms.*

# features








# to our readers

**Peripheral vascular disease** has become a major problem in the United States. Patients with peripheral vascular disease can experience a major decrease in quality of life due to painful limbs with activity. In addition, patients with peripheral vascular disease are at increased risk of amputation and death.

This year's OHI Spring Magazine is dedicated to the evaluation and treatment of peripheral vascular disease. The contents include both arterial vascular disease and venous vascular disease. Oklahoma Heart Institute now has a division that specifically specializes in the evaluation and treatment of peripheral vascular disease. The OHI Peripheral Vascular Division combines the expertise and skills of both peripheral interventional cardiologists and vascular surgeons. Their perspective on evaluation and management is illustrated by the articles in this issue.

We hope that you enjoy the articles and welcome any comments or suggestions regarding the magazine content.

Sincerely,

**Wayne N. Leimbach, Jr., MD**
*Publisher/Editor, Oklahoma Heart Institute Magazine*

**ON THE COVER**
*Guthrie Green is an urban park, arts and entertainment mecca in the heart of Tulsa's Brady Arts District. More than a place to relax and play, it's also a lab full of learning opportunities for inquisitive minds. From the geo-thermal elements beneath the park to the plants and green life above, everyone can explore, investigate, and engage in this multi-faceted outdoor classroom. Nationally recognized as one of America's most well-designed urban spaces, Guthrie Green has quickly become one of Tulsa's new iconic landmarks.*
*Photo courtesy Guthrie Green*

# Oklahoma Heart Institute Sleep Care
## *of Hillcrest Medical Center*

Oklahoma Heart Institute now offers comprehensive sleep care at our new diagnostic facility located in Columbia Plaza:

2651 E. 21st Street, Suite 400
Tulsa, OK 74114
Phone: 918.747.5337 (918.74 SLEEP)
Toll Free: 855.437.5337 (855.43 SLEEP)
Fax: 918.728.3307

The facility features 6 beds, and operates most nights per week.

**What to expect during a sleep study:**

- A warm welcome by highly qualified technicians
- An informal orientation during which the sleep study process will be explained, and you will have an opportunity to ask questions
- A comfortable, stylish and luxurious bedroom featuring:
  - Queen sized, luxury bed with pillows
  - 300+ thread count sheets
- A continental breakfast in the morning

# Peripheral Arterial Disease

*By Stanley K. Zimmerman, MD, FACC, FSCAI*

Peripheral arterial disease (PAD) is a narrowing or blockage of the arteries in the abdomen or legs leading to claudication (cramping pain that limits the ability to walk). PAD is estimated to affect nearly one-third of people over the age of 70 years of age or those 50 to 69 years of age who have a history of diabetes or smoking.

The clinical presentation of PAD may vary from no symptoms (in up to half of patients) to intermittent claudication, atypical leg pain, rest pain, ischemic ulcers, or gangrene. Patients with PAD have an increased risk of stroke, heart attack, and death. Those at risk include people less than 50 years old with diabetes, and one additional risk factor (e.g., smoking, dyslipidemia, hypertension, or hyperhomocysteinemia), age 50 to 69 years and history of smoking or diabetes, age 70 years and older, leg symptoms with exertion (suggestive of claudication) or ischemic rest pain.

People at risk of PAD include those with an abnormal lower extremity pulse examination, known atherosclerotic disease including coronary artery, carotid artery, or renal artery disease. Diabetes and smoking are the greatest risk factors, and are stronger predictors for PAD than coronary heart disease.

The prevalence of PAD is greater than that of heart failure, afflicting 8-12 million Americans. Patients with critical limb ischemia and very low ABI have an annual mortality up to 25%, and those with PAD have an annual risk of 5% of experiencing heart attack, death, or stroke. Studies have found that people with PAD are up to six times more likely to die of heart disease compared to age-matched peers. PAD is often undiagnosed and overlooked as many patient are asymptomatic. The rate of death in patients with critical PAD necessitating amputation is as high as 50% within the first 12 months after surgery. Through education, awareness, improved and expanded screening we can improve death rates and lessen amputation rates.

Through these series of articles we hope to expand knowledge on vascular services and options for treatment of this debilitating and deadly disease. By raising awareness, the rates of amputation, debility, and death related to peripheral arterial disease can be decreased and the dramatic impact it has on patients, their families, and society lessened.

*Stanley K. Zimmerman, MD, FACC, FSCAI is Co-Director of OHI Vascular Services, Medical Director OHI Vascular Imaging Laboratory, and Medical Director Cardiac Catheterization Lab Hillcrest South Hospital.*

# Critical Limb Ischemia (CLI)

*By Stanley K. Zimmerman, MD, FACC, FSCAI*

Peripheral arterial disease (PAD) is related to a blockage in any of the arteries in the upper or lower extremities or abdomen and can cause pain in the affected limb (claudication). PAD is estimated to affect 8-12 million Americans equal to that of cancer. Lower extremity peripheral arterial disease (PAD) presents as critical limb ischemia (CLI) in as many as 1 million Medicare patients annually[1] with an estimated cost to healthcare of over 3 billion dollars[2].

Despite this, major lower extremity amputation continues to be common[3]. In Oklahoma, we continue to have an amputation problem. As illustrated in Figure 1, the rates of amputation in diabetic patients within Oklahoma continues to rise in patients less than 65 years of age and has remained flat for those 65 years of age and older. Regional variations in amputations exist across the United States with rates being impacted by patient demographics such as race and socioeconomic factors, but more importantly access to intense vascular services seems to play a large role. Figure 2 shows the trends in critical limb ischemia related amputation rates and the number of vascular related procedures and interventions. The lower the rate of vascular related care and more specifically, intervention, the greater the amputation rate across all fields[4]. Through increased awareness, education, and a growing number of endovascular related interventions, amputation rates are decreasing, and have done so on a national level by approximately 50% over the last 15 years[5]. Despite this, Northeast Oklahoma has one of the second highest rates nationally with 18-21 patients per 10,000 according to Medicare databases (Figure 3) with the rest of the state with rates of 14-17 per 10,000. Some isolated areas and counties in the southeast portion of the state have rates of greater than 22 per 10,000 patients.

Reasons for this disparity are multi-factorial, but there is clear evidence that patients with progressive severe critical limb ischemia presenting with extensive gangrene, ulceration, and infection often have disease that has become so advanced they undergo amputation. Some reasons are related to poor access to care, and they often present too late for revascularization and limb salvage, which necessitates primary amputation. By providing education to patients, involving primary care providers, advanced screening, and awareness through an advanced vascular multidisciplinary approach, amputation rates may improve; however, research has suggested that increased vascular intensity is most impactful on reducing amputation rates[4].

All patients at risk for PAD should be screened with resting ankle/brachial indices and referred to a vascular specialist or set up for more advanced imaging as clinically warranted. Patients presenting with signs of critical limb ischemia with ABI less than 0.4 or absent pulses with peripheral skin changes of ulceration/gangrene should be referred immediately to a vascular medicine specialist and placed on systemic antibiotics if any skin disruption or infection is noted (Figures 4 and 5).

The next step in the critical limb algorithm is evaluating candidacy for revascularization. If the patient has a reasonable life expectancy, current guidelines recommend angiography to define arterial anatomy and assess if revascularization is possible. When revascularization is possible determining surgical versus endovascular approach is then decided.

With progressive technology patients have access to many percutaneous options for revascularization, including directional atherectomy, orbital atherectomy, laser atherectomy, rotational atherectomy, drug coated balloon angioplasty, self expanding stents, and drug eluting self expanding stents to list just a few. Patients unable to undergo revascularization should be treated medically and followed closely clinically with on-going wound care and a multi-disciplinary approach. After revascularization, patients should have continued on-going vascular surveillance at 1, 3, 6 and 12 month intervals in the first year and then annually thereafter. Aggressive risk factor and lifestyle modification is imperative with smoking cessation, statin therapy, control of diabetes and hypertension, and a supervised exercise program when available. There is only 39% compliance unfortunately with all major

Figure 1

**Amputation Rates Among Diabetics per 100,000 Medicare Patients in Oklahoma**

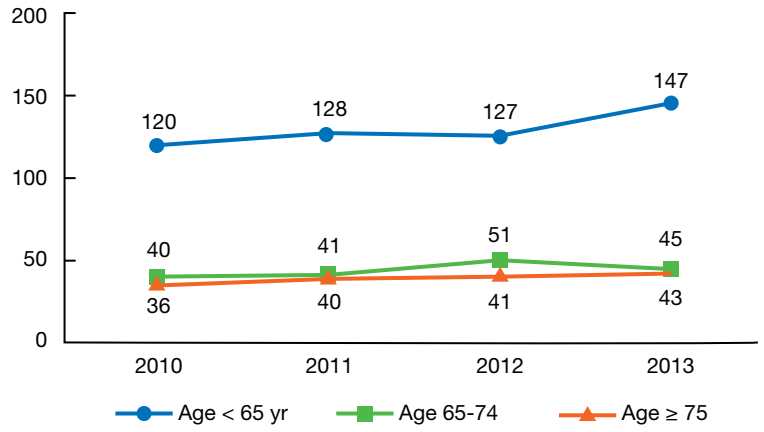


Source: healthindicators.gov

Figure 2

**Regional Rate of Amputation per 10,000 Medicare Patients**

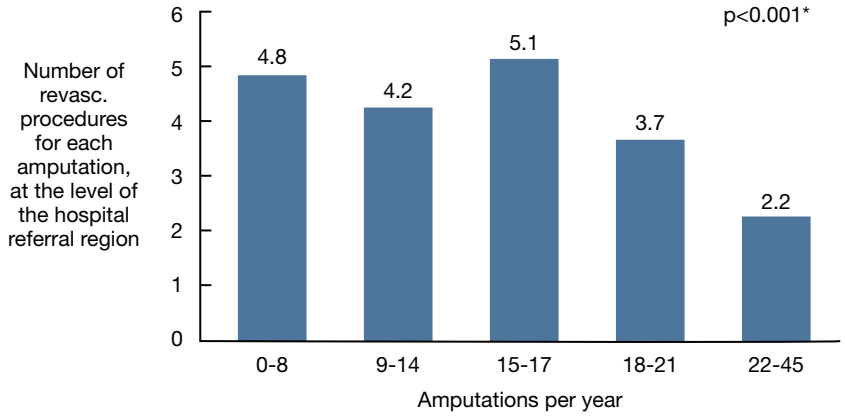


*P value is for non-parametric test of trend across all regions

Figure 3

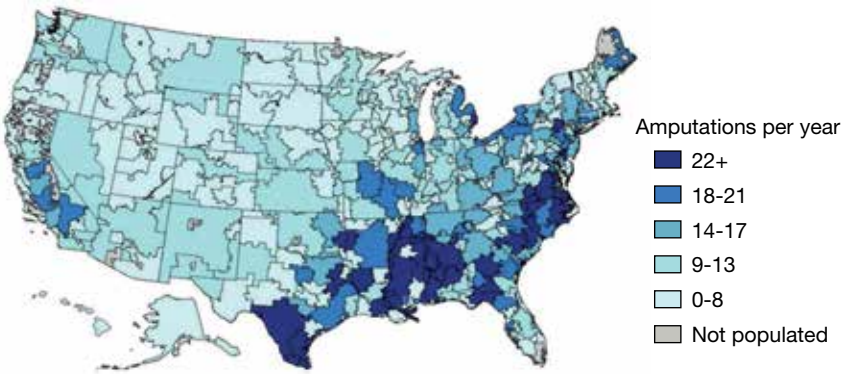


Figure 5

## Atherectomy Types


Figure 4

## ACC/AHA Guideline for the Management of PAD: Diagnosis and Treatment of Critical Limb Ischemia

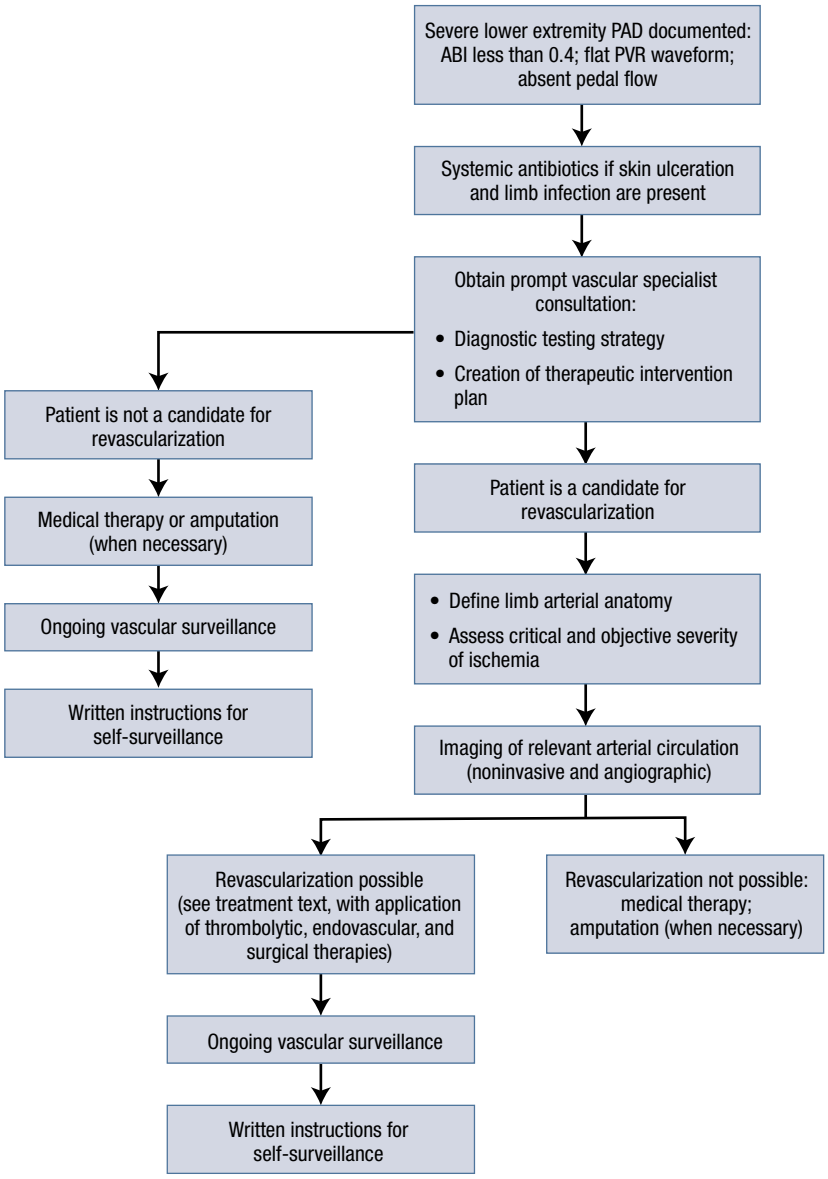


risk factor thresholds[8] with data clearly showing that all major adverse event rates are improved the closer guidelines are followed.

A team based, multi-disciplinary approach with vascular medicine, surgery, wound care, podiatry, primary care, nursing, and rehab are all critical in keeping patients amputation free. Patients with critical limb ischemia who undergo amputations have tremendously high morbidity and mortality. In fact mortality rates in this population include almost one quarter of patients dying within 30-days, and almost 50% at 1 year[9]. The ultimate goal is to keep the patient walking and avoid amputation. With regular follow-up and regular vascular testing by saving a limb we can save a life.

*Stanley K. Zimmerman is Co-Director of OHI Vascular Services, Medical Director of the OHI Vascular Imaging Lab and Medical Director of the Cardiac Catheterization Lab at Hillcrest Hospital South. He is a specialist in interventional cardiology, including cardiac catheterization, coronary angioplasty and related interventional procedures such as coronary stents, atherectomy, vascular ultrasound and peripheral vascular procedures.*

## References:

1. Selvin E, Erlinger TP. Prevalence of and risk factors for peripheral arterial disease in the United States: Results from the national health and nutrition examination survey, 1999–2000. Circulation. 2004; 110:738–743.
2. Peacock JM, Keo HH, Yu X, Oldeberg N, Duval S, Henry TD, Jaff MR, Baumgartner I, Hirsch AT. Abstract 5788: The incidence and health economic burden of critical limb ischemia and ischemic amputation in Minnesota: 2005–2007. Circulation. 2009; 120: S1148.
3. Goodney PP, Beck AW, Nagle J, Welch HG, Zwolak RM. National trends in lower extremity bypass surgery, endovascular interventions, and major amputations. Journal of Vascular Surgery. 2009; 50:54–60.
4. Goodney PP, Holman K, et.al. Regional intensity of vascular care and lower extremity amputation rates. Journal Vascular Surgery. 2013 June; 57(6): 1471–1480.e3.
5. Goodney PP, Tarulli M, et.al. Fifteen-Year Trends in Lower Limb Amputation, Revascularization, and Preventive Measures among Medicare Patients. JAMA Surg. 2015 Jan 1; 150(1): 84–86.
6. Fisher ES, Wennberg DE, Stukel TA, Gottlieb DJ, Lucas FL, Pinder EL. The implications of regional variations in Medicare spending. Part 1: The content, quality, and accessibility of care. Annals of Internal Medicine. 2003; 138:273–287.
7. Fisher ES, Wennberg DE, Stukel TA, Gottlieb DJ, Lucas FL, Pinder EL. The implications of regional variations in Medicare spending. Part 2: Health outcomes and satisfaction with care. Annals of Internal Medicine. 2003; 138: 288–298.
8. Armstrong EJ, Chen DC, et.al. Adherence to guideline-recommended therapy is associated with decreased major adverse cardiovascular events and major adverse limb events among patients with peripheral arterial disease. Journal American Heart Assoc. 2014 Apr 10; 3(2):e000697.
9. Fortington LV, Geertzen JH, et.al. Short and long term mortality rates after a lower limb amputation. European Journal Vascular Endovascular Surg. 2013 Jul; 46(1):124-31.

# Alternative Access in Revascularization of Critical Limb Ischemia

*By Stanley K. Zimmerman, MD, FACC, FSCAI*

Patients with chronic critical limb ischemia often have complex anatomical disease that many times requires multiple approaches to obtain revascularization. Aggressive techniques are currently being utilized for limb salvage and to improve wound healing in order to avoid amputation, which portends an extremely high mortality rate particularly in the first year after amputation[1].

## TECHNIQUES FOR LOWER EXTREMITY INTERVENTION

The traditional approach for lower extremity intervention entails a cross over approach. In this approach access is gained in the unaffected limb or less symptomatic limb on the contra lateral side femoral artery. After gaining wire access up and over the aorta iliac bifurcation, a sheath is advanced over the wire into the affected limb and placed into the common femoral or superficial femoral artery (Figure 1). Alternatives to this strategy exist when aortic-iliac anatomy is complicated by a difficult calcified bifurcation with significant angulation, severe iliac disease, or diffuse common femoral artery disease. When this occurs brachial or radial access may be utilized.

Another alternative strategy is ipsilateral antegrade access, where access is obtained in the affected limb in line with blood flow or antegrade to blood flow. In this approach access is obtained at the common femoral artery below the inguinal ligament and the sheath is advanced in the ipsilateral leg. The antegrade approach is associated with higher rates of bleeding complications and is unsuitable for ostial SFA or distal common femoral artery disease[2]. Access via the popliteal artery in a retrograde manner is also utilized when the antegrade approach is unsuccessful or not possible due to anatomic reasons. The popliteal artery is accessed with ultrasound guidance and a sheath is placed retrograde to allow intervention. Intervention can be performed from this access or combined with contra lateral cross over approach or ipsilateral approach where the wire is externalized and used to "floss" the lesion. Intervention can then be performed in an antegrade manner.

The complex anatomical nature of chronic critical limb ischemia often necessitates a variety of these approaches due to complete occlusions involving the superficial femoral or popliteal arteries. In many cases the infra trifurcation vessels of the lower extremity are involved and may be completely occluded as well, which makes pedal access a valuable approach.

Figure 1

**Array of Access Strategies for Femoral Popliteal Intervention**

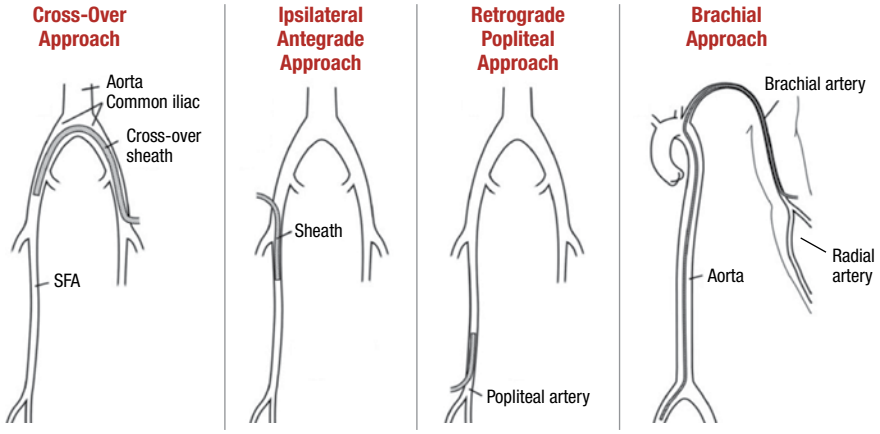


Source: Casserly et al, Practical Peripheral Vascular Intervention

Figure 2

**Views of Alternative Access Methods**

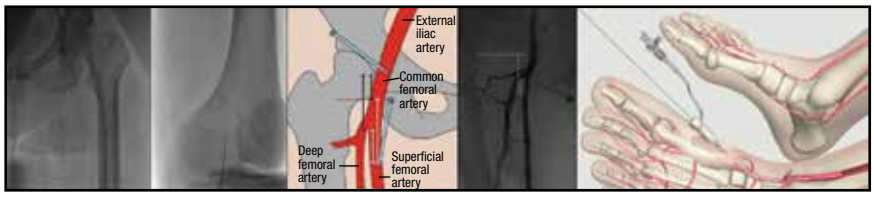


Cross-over, Popliteal, Antegrade, and Pedal

## TAMI TECHNIQUE

Tibiopedal arterial minimally invasive retrograde revascularization (TAMI technique) is a revascularization modality by which the operator obtains tibiopedal access and revascularizes the lower extremity via tibial access only. TAMI is an approach that utilizes ultrasound guided access into the dorsalis pedis, posterior tibial, or even peroneal arteries and offers considerable advantages. The small diameter of tibial vessels may help to increase the stiffness of resistance thus making advancement of a catheter or wire through the occlusion easier. It is also commonly experienced that the distal cap or the distal aspect of the occlu-

Figure 3

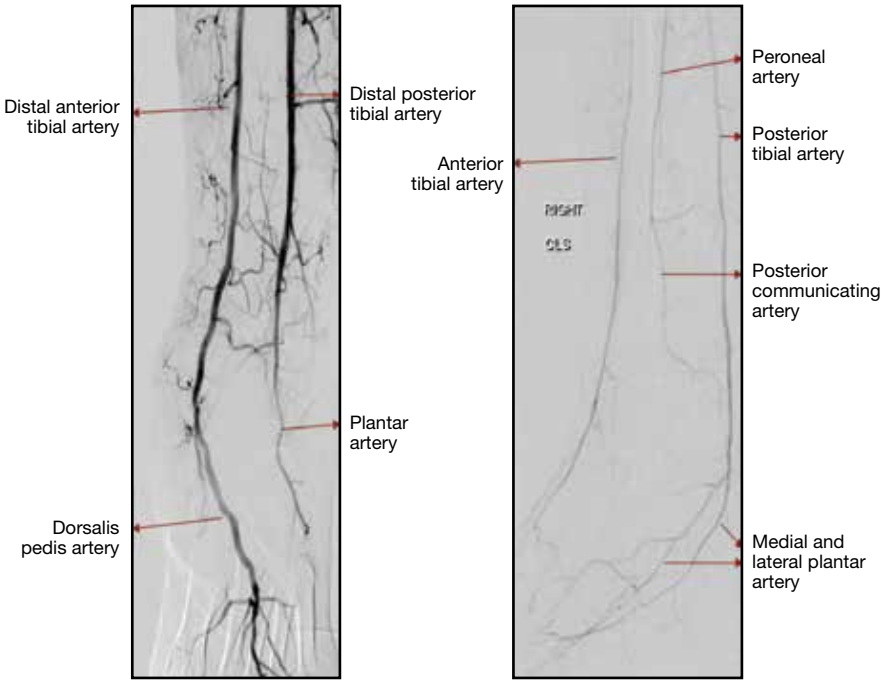


Courtesy Cook Medical and Mousa et.al, Endovascular Today, Jan 2012, Cook Medical, Bloomington, IN

Figure 4

Courtesy Cook Medical and Mousa et al, Endovascular Today, Jan 2012, Cook Medical, Bloomington, IN

*Vascular medicine as a field continues to evolve and grow to meet the ever-changing demands of complex peripheral arterial disease.*

sion tends to be softer and thus easier to penetrate than the more resistant proximal cap or proximal occlusion.

Finally, the pedal approach may offer a shorter arterial segment to cross for intervention when compared to the traditional approaches, and may offer a safer approach in morbidly obese patients when groin access has increased bleeding risk[5]. Potential disadvantages of pedal access are that the vessels of the foot are small diameter vessels and thus are prone to spasm and dissection. These arteries very frequently are calcified, and access near the ankle may cause significant difficulty in sheath advancement due to significant angulation.

Procedures can be complicated due to difficult access which often means long procedure times and excess contrast utilization. The access vessel may also be one of the lone remaining infrapopliteal vessels and should it be damaged via dissection perforation or thrombosis, acute ischemia could ensue prompting need for emergent amputation. Despite this, retrograde pedal access for limb salvage in high-risk patients is feasible and safe, with acceptable limb salvage rates at intermediate follow-up. It is an appropriate approach in patients who have failed an antegrade intervention and are poor candidates for a tibial bypass[6]. When performed by experienced operators, it has proven to decrease amputation rates and improve wound healing[7].

One thing is clear, regardless of the approach to chronic critical limb ischemia, a multi-disciplinary approach involving vascular medicine, surgery, wound care, primary care providers, and nursing is essential for reducing the morbidity and mortality associated with this process. Patients often have co-existing cardiovascular issues and should be screened appropriately during the evaluation period. Essential to patients having improved outcomes and procedural success is case selection and operator experience.

Vascular medicine as a field continues to evolve and grow to meet the ever changing demands of complex peripheral arterial disease. As evidenced by continued amputations throughout the nation and the world, improving awareness of the problem with early recognition and referral to vascular medicine specialists is critical to making an impact on a disease process that has such a large impact on patients, their families, and to society and the medical community as a whole.

*Stanley K. Zimmerman is Co-Director of OHI Vascular Services, Medical Director of the OHI Vascular Imaging Lab and Medical Director of the Cardiac Catheterization Lab at Hillcrest Hospital South. He is a specialist in interventional cardiology, including cardiac catheterization, coronary angioplasty and related interventional procedures such as coronary stents, atherectomy, vascular ultrasound and peripheral vascular procedures.*

## References:

1. Fortington LV, Geertzen JH, et.al. Short and long term mortality rates after a lower limb amputation. Eur J Vasc Endovasc Surg. 2013 Jul; 46(1):124-31.
2. Casserly, I, Sachar, R, et.al. Practical Peripheral Vascular Intervention. 2nd Edition. Philadelphia: Lippincott Williams, 2011. Print.
3. Gutzeit, A, Graf. Ultrasound-guided antegrade femoral access: comparison between the common femoral artery and the superficial femoral artery. European Radiology. June 2011, Volume 21, Issue 6, pp 1323-1328.
4. Saab, F, Mustapha, J. TAMI: A New Technique in Critical Limb Ischemia Revascularization. Endovascular Today. Supplement. 2014 March: 1-5.
5. Mousa, A, Dieter, R, et.al. Anatomy of the Pedal Arch and Implications for Tibiopedal Access. Endovascular Today. Supplement. 2012 January: 3-5.
6. Bazan HA, Le L, et.al. Retrograde pedal access for patients with critical limb ischemia. Journal Vascular Surgery. 2014 Aug; 60(2):375-81.
7. Goodney PP, Holman K, et.al. Regional intensity of vascular care and lower extremity amputation rates. Journal Vascular Surgery. 2013 June; 57(6): 1471–1480.e3.

# Towards a More Durable Result in the Peripheral Arteries

*By David Liff, MD*

Peripheral artery disease is a common disease affecting between 8-12 million Americans. While the prevalence of PAD is over 10% in the overall population of adults > 65 years old, certain populations have much higher rates of disease. Amongst adults > 70, or > 65 years old with a history of smoking or diabetes, 30% of people have evidence of peripheral vascular disease. With an aging population and increasing rates of diabetes, the population of patients with peripheral artery disease is likely to greatly increase.

Parallel to the increasing population of patients with PAD, the field of endovascular peripheral interventions has grown considerably. In the last 15 years, the number of endovascular procedures has grown by over 400%, aided by an increasing array of devices and tools to better serve patients. As technologic advances have allowed for patients with more complex disease to be successfully treated with endovascular, as opposed to surgical procedures, the professional societies have adjusted their criteria regarding which patients may be appropriately treated with endovascular interventions.

Restenosis is the renarrowing of blockages in arteries after they have been appropriately dilated, and is the achilles heel of peripheral interventions. In more recent peripheral artery trials, restenosis occurs in 20-40% of patients at 2 years. Restenosis is a complex biological process that occurs as the artery attempts to heal from the trauma caused by the original intervention and leads to renarrowing and sometimes reocclusion of the artery. For claudication patients, restenosis may mean a return of disabling symptoms, while for critical limb ischemia patients it may lead to new wounds and threatened amputations.

There are multiple factors contributing to high rates of restenosis in the peripheral arteries. The leg arteries are remarkable for their ability to stretch, bend, and twist with the movement of hip, knee and foot joints. The superficial femoral artery, stretches 13% and twists 60 degrees with hip and knee flexion. Furthermore, the leg arteries are subject to bending and compression forces from the surrounding leg muscles. This contributes to the diffuse disease often encountered in the peripheral arteries, and we know that the longer and more diffuse the underlying disease, the greater the rates of restenosis following successful interventions.

In the coronary arteries, the introduction of stents coated in medications that powerfully inhibit the biologic restenosis cascade has impressively decreased the need for repeat interventions.

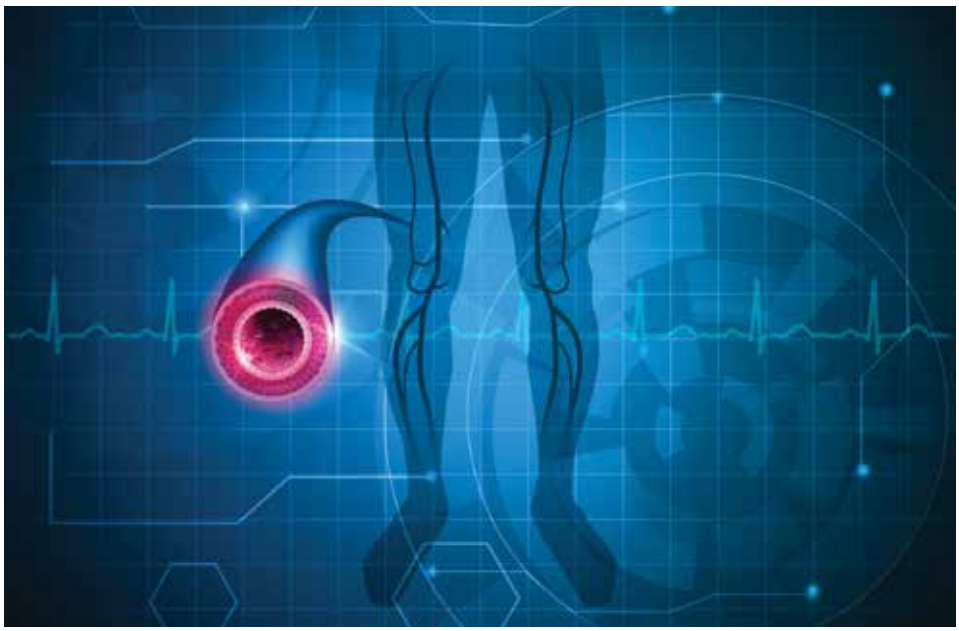

The Zilver PTX stent (Cook medical, Bloomington, IN) is a semi-rigid nitinol stent made for peripheral artery disease that is covered in paclitaxel, which then dissolves into the artery over time, inhibiting the growth of neointima and restenosis. It has been shown to be significantly better than both angioplasty alone and non-medicated stents. However, the problem with this approach is that a stent is left in the artery forever. It is thought that the introduction of a semi-rigid stent into the periphery alters the arteries' ability to stretch and shorten, leading to kinking, trauma, and possible stent fracture. Thus, the stent itself may ultimately increase the likelihood of restenosis in the long term.

The development of drug coated balloons for the peripheral arteries is a promising approach to opening peripheral artery blockages without the need for stents. The technology consists of a conventional angioplasty balloon coated in a polymer that distributes a drug to the vessel wall that inhibits the restenosis cascade, while simultaneously dilating the artery. The advantage is that the artery is opened by angioplasty, and a drug is delivered directly to the vessel to prevent restenosis and avoid the need for stent placement. Several studies have been conducted that show drug coated balloons are effective at opening arteries and preventing restenosis up to 2 years. When compared to historical results of stent trials, the drug coated balloons have shown to be equally effective, all without introducing any permanent implant into the artery.

Currently, at Oklahoma Heart Institute, we frequently employ drug coated balloons to minimize the use of stents. Often this is done in conjunction with atherectomy devices that remove some of the atherosclerotic burden prior to angioplasty. We find that, by modifying and removing part of the plaque, we are able to more easily open the vessel with a balloon, reducing baurotrauma from angioplasty as well as the need for stents, and, hopefully, decreasing the intensity of the restenosis process. In addition, the delivery of anti-restenotic medications directly to the vessel wall with the drug coated balloons is hoped to be incrementally more effective at reducing repeat interventions due to restenosis.

At Oklahoma Heart Institute, we believe that our use of such an approach helps our patients achieve good long term patency rates with fewer interventions. Our goal is to use the strengths and limitations of the various technologies available to build novel and cutting edge approaches to vascular interventions, so that we can achieve better results for patients and contribute to the advancement of the field.

*David Liff, MD is an interventional cardiologist who specializes in peripheral vascular disease as well as coronary interventional disease.*

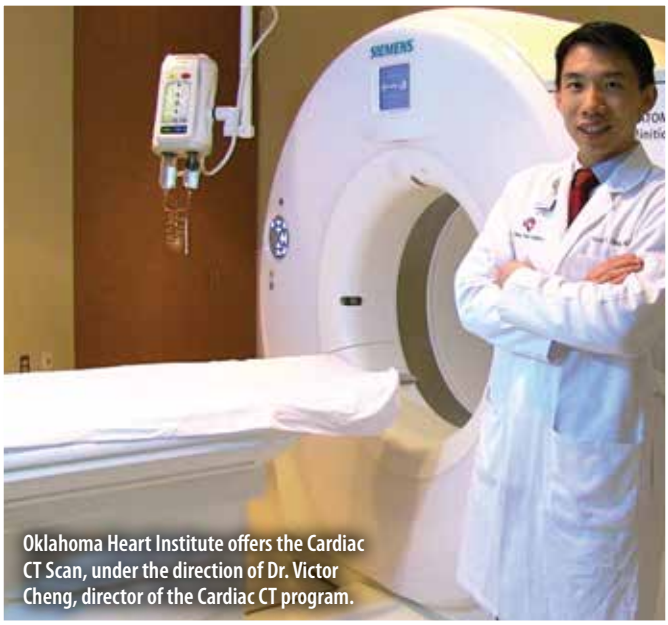


Oklahoma Heart Institute offers the Cardiac CT Scan, under the direction of Dr. Victor Cheng, director of the Cardiac CT program.

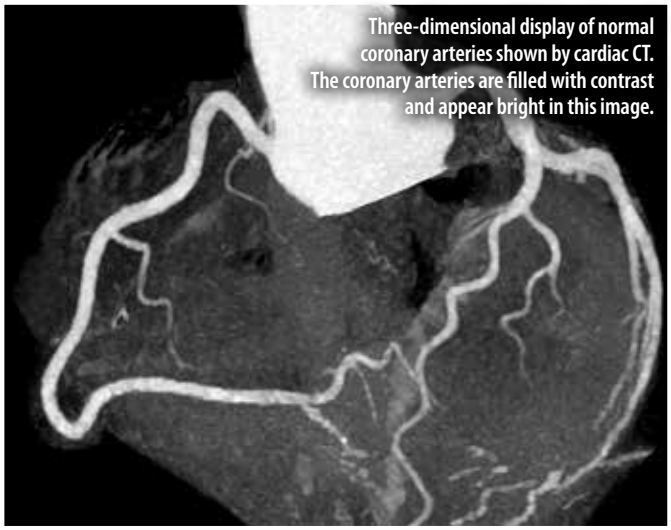

Three-dimensional display of normal coronary arteries shown by cardiac CT. The coronary arteries are filled with contrast and appear bright in this image.


# Cardiac CT at Oklahoma Heart Institute

*State-of-the-art scanner detects your risk for heart disease*

Heart disease is the leading cause of death in the United States for men and women. But for many, the first symptom of heart disease is a heart attack.

In Tulsa, Oklahoma Heart Institute is changing that by offering a Cardiac CT Scan performed by a state-of-the-art ultrafast scanner that is more than 95 percent sensitive in detecting heart disease. The scanner creates detailed and accurate images of the heart and arteries in just seconds, all meaning easy and early detection of heart disease.

Dr. Victor Cheng administers this new technology at Oklahoma Heart Institute. Cheng, who came to OHI via Los Angeles' Cedars-Sinai Hospital, says using the Cardiac CT Scan is a good way to test if a patient's symptoms are due to heart disease or if a patient with significant risk factors has developed heart disease.

"For both symptomatic and asymptomatic individuals, Cardiac CT detects the presence and amount of plaque in the coronary arteries," Cheng says. "This information helps doctors tailor the intensity of recommended therapies to reduce heart attack risk and can motivate individuals to live a more heart-healthy lifestyle."

He adds, "For individuals with chest pain or breathlessness, Cardiac CT is the most reliable noninvasive test to show that the person does not have significant coronary artery blockage. The use of Cardiac CT in this situation determines whether additional evaluation or treatment for coronary artery disease is needed."

Cardiac CT is a painless screening test that uses an X-ray machine to take clear, detailed pictures of a heart and blood vessels. The scanner uses 50-90 percent less radiation than earlier generation scanners. The average patient is exposed to a radiation dosage comparable to a mammogram. This one-time radiation exposure is considered quite safe.

For individuals concerned about, or are at risk for, heart disease, Cardiac CT detects if there is no disease, mild disease or severe disease. Cardiac CT also effectively determines presence of heart disease in those who have undergone a stress test with an inconclusive result.

**Oklahoma Heart Institute**
**1120 S. Utica Ave.**
**1265 S. Utica Ave., Suite 300**
**9228 S. Mingo Road, Suite 200**
**8801 S. 101st E. Ave.**
**918-592-0999**
**www.oklahomaheart.com**

# Oklahoma Heart Institute

# SERVICES

www.oklahomaheart.com

## Interventional Cardiology

- Cardiac Catheterization
- Coronary Angioplasty
- Coronary Stents
- Multivessel Angioplasty and Stenting
- Atherectomy
- Rotablator Atherectomy
- Thrombolytic Therapy
- Carotid Stenting
- Fractional Flow Reserve
- Intravascular Ultrasound
- Intracardiac Echo
- Paravalvular Leak Plugs
- Myocardial Biopsy
- Pericardiocentesis
- Peripheral Angioplasty
- Peripheral Stents
- Percutaneous ASD Closures
- Percutaneous PFO Closures
- Impella Circulatory Support
- Therapeutic Hypothermia for Cardiac Arrest Patients
- Transcatheter Aortic Valve Replacement (TAVR)
- Transcatheter Mirtral Valve Repair
- Venous Ablation
- Aspiration Venous Thrombolic Obstructive Disease

## Noninvasive Cardiology

- CT Angiography
- CT Heart Scan
- Cardiac and Vascular Screening Services
- Nuclear Cardiology
- Echo and Doppler Studies
- Nuclear and Echocardiographic Exercise and Pharmacological Stress Testing
- Retinal Imaging
- Thyroid Ultrasound
- Transesophageal Echocardiography, Arterial Venous Peripheral Vascular Imaging and Doppler Studies
- Peripheral Arterial Doppler and Duplex Imaging
- Cardiovascular Magnetic Resonance Imaging
- External Counterpulsation (ECP) Therapy
- Transcranial Doppler
- Aquapheresis Therapy

## Electrophysiology

- Electrophysiology Studies
- Ablation Therapy
- Pacemaker Implantation
- Pacemaker and Lead Extraction
- Pacemaker Programming
- Pacemaker Monitoring and Clinic
- Implantable Cardioverter Defibrillator (ICD) Replacement
- ICD and Hardware Removal
- ICD Programming
- ICD Monitoring and Clinic
- Holter Monitoring and Interpretation
- 30 Day Cardiac Event Monitors
- Implantation and Interpretation of Long-Term Heart Monitors
- Signal Averaged EKGs and Interpretation
- Head Up Tilt Testing and Interpretation
- Direct Current Cardioversion
- Antiarrhythmic Drug Loading and Monitoring

## Metabolic Disorders

- Diabetes
- Thyroid
- Hypertension
- Other Endocrine Problems

## Specialty Clinics

- Advanced Center for Atrial Fibrillation
- Dysrhythmia and Pacer Clinic
- Hypertension Clinic
- Resistant Hypertension Clinic
- Adolescent and Adult Congenital Heart Clinic
- Lipid and Wellness Clinic
- Heart Failure Clinic
- Same Day Appointment Clinic
- Pre-Operative Clinic
- Center for the Treatment of Venous Disease
- Sleep Care
- Center for Peripheral Arterial Disease
- The Valve Clinic

## Cardiovascular Surgery

### CARDIAC SURGERY

- Coronary Artery Bypass
- Surgical Aortic Valve Replacement
- Transcatheter Aortic Valve Replacement with TAVR Team
- Mitral and Tricuspid Valve Repair and Replacement
- Surgical Treatment of Atrial Fibrillation: “Mini-Maze”, Full Maze, Left Atrial Appendage Ligation
- Cardiac Tumor Resection

### THORACIC NON-CARDIAC SURGERY

- VATS (Video Assisted Thoracoscopy Surgery) for Biopsy and Treatment
- Minimally Invasive and Open Techniques for Diagnosis and Staging of Lung and Nonpulmonary Cancer in the Chest
- Minimally Invasive and Open Techniques for Therapeutic Lung Cancer Resection
- Surgical Treatment of Esophageal Cancer and Benign Esophageal Conditions

### VASCULAR SURGERY

- Endovascular and Open Treatment of Aortic Aneurysms: Abdominal and Thoracic Diagnosis, Surgical, Interventional and Medical Management of Peripheral Arterial Disease (PAD)
- Surgical Treatment of Carotid Occlusive Disease
- Limb Salvage

### MEDIASTINAL SURGERY

- Evaluation and Treatment of Mediastinal Masses

### THYROID/ENDOCRINE SURGERY

- Full Spectrum of Thyroid Surgery (Total versus Near Total Thyroidectomy)
- Parathyroid Surgery with Intraoperative PTH monitoring
- Recurrent Nerve Monitoring


**Oklahoma Heart Institute Hospital**
1120 Utica Avenue
Tulsa, OK 74104
P) 918.574.9000

**Oklahoma Heart Institute at Utica Physicians Offices**
1265 S. Utica Avenue
Tulsa, OK 74104
P) 918.592.0999 • F) 918.595.0208

**Oklahoma Heart Institute at Southpointe Physicians Offices**
9228 S. Mingo Road
Tulsa, OK 74133
P) 918.592.0999 • F) 918.878.2408

**Oklahoma Heart Institute At Hillcrest Hospital South**
8801 S. 101st E. Avenue
Tulsa, OK 74133
P) 918.592.0999

# THE DOCTORS OF OKLAHOMA HEART INSTITUTE

### Wayne N. Leimbach, Jr., MD, FACC, FACP, FSCAI, FCCP, FAHA

Dr. Leimbach is a specialist in interventional and structural cardiology, including cardiac catheterization, coronary angioplasty, stents, atherectomy, laser, intravascular ultrasound imaging, and direct PTCA/stents for acute myocardial infarction. He also specializes in percutaneous closure of PFOs, ASDs, PDAs and percutaneous valve replacement or repair procedures such as TAVR and MitraClip. He is Director of the Cardiac and Interventional Laboratories at Oklahoma Heart Institute Hospital and also is Past Chief of Cardiology. Dr. Leimbach is Co-Founder of the Lipid and Wellness Clinic at Oklahoma Heart Institute. He is Director of the James D. Harvey Center for Cardiovascular Research at Hillcrest Medical Center, as well as Director of the Oklahoma Heart Research and Education Foundation. He also serves as Clinical Associate Professor of Medicine at the University of Oklahoma College of Medicine-Tulsa. Dr. Leimbach completed a Clinical Cardiology Fellowship and a Research Fellowship at the University of Iowa Hospitals and Clinics. He also completed his Internal Medicine Internship and Residency Programs at Iowa, where he was selected Chief Resident in Medicine. He received his medical degree from Northwestern University in Chicago and his Bachelor of Science degree from the University of Michigan.

*Board certified in Internal Medicine, Cardiovascular Disease and Interventional Cardiology*

### Robert C. Sonnenschein, MD, FACC, ASE, RVT, RPVI

Dr. Sonnenschein specializes in echocardiography and noninvasive peripheral vascular imaging. He is Director of Echocardiography at Hillcrest Hospital South and past Director of Peripheral Vascular Ultrasound Imaging at Hillcrest Medical Center and Oklahoma Heart Institute and serves as Clinical Associate Professor of Medicine at the University of Oklahoma College of Medicine – Tulsa. He completed his Cardiology Fellowship at the State University of New York Upstate Medical Center in Syracuse, where he also completed his Internal Medicine Internship and Residency programs. Dr. Sonnenschein received his medical degree from Rush Medical College in Chicago and his Bachelor of Arts degree from the University of Pennsylvania.

*Board certified in Internal Medicine, Cardiovascular Disease, and Adult Echocardiography Registered Vascular Technologist*

### Robert E. Lynch, MD, FACC

Dr. Lynch is a specialist trained in noninvasive and invasive cardiology with a special interest in the prevention of cardiovascular disease. He is former Chief of Cardiology at Hillcrest Medical Center, where he also has served as Chief of Medicine and President of the medical staff. Dr. Lynch is former Co-Director of the Lipid and Wellness Clinic at Oklahoma Heart Institute and Director of the Executive Health Program. Dr. Lynch is also a Clinical Assistant Professor at the University of Oklahoma College of Medicine – Tulsa. He completed his Cardiology Fellowship, as well as his Internal Medicine Internship and Residency, at the University of Oklahoma Health Sciences Center. Dr. Lynch received his medical degree from the University of Oklahoma School of Medicine and his Bachelor of Science degree from the University of Tulsa. Before establishing his practice in Tulsa, he served as Chief of Medicine at the U.S. Army Hospital, Bangkok, Thailand.

*Board certified in Internal Medicine and Cardiovascular Disease*

### James J. Nemec, MD, FACC

Dr. Nemec is a specialist in echocardiography, stress echocardiography and nuclear cardiology. He serves as Director of Nuclear Cardiology for Oklahoma Heart Institute. Dr. Nemec has served as Assistant Professor of Internal Medicine, Division of Cardiology, at Creighton University and as Assistant Professor, Department of Radiology, also at Creighton University. He completed his Clinical Cardiology Fellowship at the Cleveland Clinic Foundation and his Internal Medicine Internship and Residency at Creighton University. Dr. Nemec also completed a year of training in pathology at the University of Missouri, Columbia, MO. He received his medical degree from Creighton University, where he also received his Bachelor of Arts degree.

*Board certified in Internal Medicine, Cardiovascular Disease and Nuclear Cardiology*

### Gregory D. Johnsen, MD, FACC, FSCAI

Dr. Johnsen is an interventional cardiologist with expertise in cardiac catheterization, angioplasty and related interventional procedures, such as stents and atherectomy. He is Director of Cardiac Rehabilitation at Hillcrest Medical Center and Director of the Hillcrest Exercise and Lifestyle Programs. He completed his Clinical Cardiology Fellowship at the University of Oklahoma – Oklahoma City, where he then finished an extra year of dedicated training in interventional cardiology. He completed his Internal Medicine Internship and Residency training at the University of Oklahoma – Oklahoma City, where he also received his medical degree. Dr. Johnsen received his Bachelor of Science degree from Oklahoma State University.

*Board certified in Internal Medicine, Cardiovascular Disease and Interventional Cardiology*

### Alan M. Kaneshige, MD, FACC, FASE

Dr. Kaneshige is a noninvasive cardiologist with expertise in adult echocardiography, stress echocardiography and transesophageal echocardiography. He is Director of Congestive Heart Failure at Oklahoma Heart Institute and Past Chief of Cardiology at Hillcrest Medical Center. Dr. Kaneshige completed his Internal Medicine Internship and Residency at Creighton University School of Medicine, where he also received his medical degree. He received a Bachelor of Science in chemistry at Creighton University. Dr. Kaneshige completed his Clinical Cardiology fellowship at Creighton, where he also served as Chief Cardiology Fellow for two years. He completed an additional Cardiac Ultrasound Fellowship at the Mayo Clinic in Rochester. Dr. Kaneshige served as Assistant Professor of Medicine at Creighton University School of Medicine, where he was Director of the Noninvasive Cardiovascular Imaging and Hemodynamic Laboratory.

*Board certified in Internal Medicine, Cardiovascular Disease, Adult and Transesophogeal Echocardiography*

### Edward T. Martin, MS, MD, FACC, FACP, FAHA

Dr. Martin is a noninvasive cardiologist with subspecialty expertise in noninvasive imaging. He is Director of Cardiovascular Magnetic Resonance Imaging at Oklahoma Heart Institute and Hillcrest Medical Center. In addition, he is a Clinical Associate Professor of Medicine at the University of Oklahoma College of Medicine – Tulsa. Dr. Martin has specialty training in Nuclear Medicine, as well as additional training dedicated to Cardiovascular Magnetic Resonance Imaging. He completed his Cardiology Fellowship at the University of Alabama and Internal Medicine Internship/Residency training at Temple University Hospital in Philadelphia. He received his medical degree from the Medical College of Ohio. Dr. Martin completed his Master of Science degree in mechanical engineering at the University of Cincinnati and his Bachelor of Science degree in physics at Xavier University. Dr. Martin is a founding member of the Society of Cardiovascular Magnetic Resonance and is a past editorial board member of the Journal of Cardiovascular Magnetic Resonance. Dr. Martin has also been actively involved with the American College of Cardiology (ACC) on a national level participating on numerous committees, writing groups and leadership positions. He is the current ACC Governor of the State of Oklahoma. He is also a 2 time past President of the Board of Directors of Tulsa Metropolitan Division of the American Heart Association and past President of the Intersocietal Commission for the Accreditation of Magnetic Resonance Laboratories (ICAMRL). Locally, he is the current Director of Cardiovascular MRI at OHI and the current Vice Chief of Staff at Hillcrest Hospital South.

*Board certified in Internal Medicine and Cardiovascular Disease*

### Roger D. Des Prez, MD, FACC

Dr. Des Prez is a noninvasive cardiologist with specialty expertise in echocardiography, nuclear cardiology and cardiac computed tomography. He is Director of Cardiac Computed Tomography Services of the Cardiology Department at Bailey Medical Center. Dr. Des Prez received his medical degree and Bachelor of Arts degree from Vanderbilt University. He completed his Residency in Internal Medicine and Pediatrics at University Hospital of Cleveland. Dr. Des Prez practiced for six years as an internist with the Indian Health Services in Gallup, NM. He returned to Vanderbilt University as a member of the Internal Medicine Faculty, at which time he also completed his cardiology training.

*Board certified in Internal Medicine, Cardiovascular Disease, Echocardiography, Pediatrics and Nuclear Cardiology*

### Christian S. Hanson, DO, FACE

Dr. Hanson is a specialist in Endocrinology, Metabolism and Hypertension at Oklahoma Heart Institute with expertise in diabetes, lipids and hypertension. He also serves as Clinical Associate Professor of Medicine in the College of Osteopathic Medicine – Oklahoma State University. He completed a Fellowship in Endocrinology, Metabolism and Hypertension at the University of Oklahoma in Oklahoma City. Dr. Hanson's Internal Medicine Residency and Rotating Internship were completed at Tulsa Regional Medical Center. He received his medical degree from Oklahoma State University and his Bachelor of Science degree from Northeastern Oklahoma State University in Tahlequah.

*Board certified in Internal Medicine, Endocrinology and Metabolic Diseases*

### David A. Sandler, MD, FACC, FHRS

Dr. Sandler is a cardiologist with subspecialty expertise in electrophysiology, complex ablation, and atrial fibrillation management. Dr. Sandler is Director of Electrophysiology at Oklahoma Heart Institute Hospital. He completed his Cardiac Electrophysiology Fellowship and his Cardiovascular Medicine Fellowship at New York University Medical Center, New York, NY. Dr. Sandler performed his Internal Medicine Internship and Residency at Mount Sinai Medical Center, New York, NY. He earned his medical degree from Georgetown University School of Medicine in Washington, DC. Dr. Sandler received his Bachelor of Arts degree at the University of Pennsylvania in Philadelphia.

*Board certified in Internal Medicine, Cardiovascular Disease and Cardiac Electrophysiology*

### Raj H. Chandwaney, MD, FACC, FSCAI, FSVM

Dr. Chandwaney is an interventional cardiologist with expertise in cardiac catheterization, coronary angioplasty and related interventional procedures such as coronary stents, atherectomy, intravascular ultrasound and peripheral vascular interventional procedures. Dr. Chandwaney is Chief of Cardiology and Director of the Chest Pain Center and Cardiology Telemetry Unit at Oklahoma Heart Institute Hospital. He completed his Clinical Cardiology Fellowship at Northwestern University Medical School in Chicago, IL., where he also completed an Interventional Cardiology Fellowship. Dr. Chandwaney's Internal Medicine Internship and Residency were performed at Baylor College

of Medicine in Houston, TX. He received his medical degree from the University of Illinois at Chicago. Dr. Chandwaney completed his Master of Science degree at the University of Illinois at Urbana-Champaign, where he also received his Bachelor of Science degree.

*Board certified in Internal Medicine, Cardiovascular Disease, Interventional Cardiology and Endovascular Medicine*

### D. Erik Aspenson, MD, FACE, FACP

Dr. Aspenson is a subspecialist in Endocrinology, Metabolism and Hypertension at Oklahoma Heart Institute, with expertise in diabetes, lipids, hypertension and thyroid diseases. He completed a fellowship in Endocrinology at Wilford Hall Medical Center, Lackland AFB, Texas. Dr. Aspenson's Internal Medicine Internship and Residency were completed at David Grant Medical Center, Travis AFB, California where he served as Chief Resident. He received his medical degree from the University of Oklahoma and his Bachelor of Science degree at Oklahoma State University.

*Board certified in Internal Medicine, Endocrinology and Metabolic Diseases*

### Frank J. Gaffney, MD, FACC

Dr. Gaffney is an interventional and noninvasive cardiologist with subspecialty expertise in transesophageal echocardiography, nuclear cardiology, and coronary angiography. Dr. Gaffney is Director of Cardiology at Bailey Medical Center. He completed his Cardiovascular Medicine Fellowship at Scott & White Memorial Hospital in Temple, Texas. Dr. Gaffney completed his Internal Medicine Internship and Residency at Brooke Army Medical Center in San Antonio. He then remained on staff at Scott & White Memorial Hospital for several years, before entering his Fellowship in Cardiovascular Medicine. Dr. Gaffney earned his medical degree from New York Medical College, Valhalla, New York, and he received his Bachelor of Arts degree at Hofstra University in Hempstead, New York.

*Board certified in Internal Medicine, Cardiovascular Disease and Nuclear Cardiology*

### Eric G. Auerbach, MD, FACC

Dr. Auerbach is a general cardiologist whose major interest is preventive cardiology and cardiovascular risk reduction. He completed his cardiology fellowship at the University of Miami/Jackson Memorial Hospital in Miami, FL, following which he obtained additional subspecialty training in cardiovascular MRI, nuclear cardiology, and cardiac CT imaging. His areas of expertise also include echocardiography, stress testing and management of lipid disorders. In addition to holding board certification in cardiovascular disease, he is a diplomat of the American Board of Clinical Lipidology. Dr. Auerbach's Internal Medicine Internship and Residency were performed at the University of Miami/Jackson Memorial Hospital. He earned his medical degree at the University of Miami, Miami, FL, and his Bachelor of Arts degree at Princeton University, Princeton, NJ. Dr. Auerbach is the Director of Preventive Cardiology at Oklahoma Heart Institute, the medical director of The Weight Loss & Wellness Center at Oklahoma Heart Institute and a Clinical Associate Professor of Medicine at the University of Oklahoma College of Medicine – Tulsa.

*Board certified in Internal Medicine, Cardiovascular Disease and Nuclear Cardiology*

### Robert L. Smith, Jr., MSc, MD, FACC, FSCAI

Dr. Smith specializes in interventional cardiology including cardiac catheterization, coronary angioplasty, and related interventional procedures such as coronary stents, atherectomy, intravascular ultrasound, and peripheral vascular interventional procedures. Dr. Smith is Director of Cardiology and the Cardiac and Interventional Laboratories at Hillcrest Hospital South. He completed an Interventional Cardiology Fellowship at the University of Florida College of Medicine in Jacksonville, FL. Dr. Smith performed his Clinical Cardiology Fellowship at Vanderbilt University School of Medicine in Nashville, TN and Tulane University School of Medicine in New Orleans. He received his medical degree from the University of Oklahoma College of Medicine in Oklahoma City and then completed his Internal Medicine Internship and Residency at Emory University School of Medicine in Atlanta, GA. Dr. Smith received his Bachelor of Arts, Bachelor of Science and Master of Science degrees at the University of Oklahoma in Norman, OK.

*Board certified in Internal Medicine, Cardiovascular Disease, Interventional Cardiology and Nuclear Cardiology*

### Craig S. Cameron, MD, FACC, FHRS

Dr. Cameron is a specialist in cardiac electrophysiology, including catheter ablation of arrhythmia, atrial fibrillation management, pacemakers, implantable defibrillators, and cardiac resynchronization devices. Dr. Cameron is Director of Electrophysiology at Hillcrest Hospital South. He completed his Cardiac Electrophysiology Fellowship and his Cardiovascular Disease Fellowship at Baylor University Medical Center in Dallas, TX. Dr. Cameron's Internship and Internal Medicine Residency were performed at Baylor College of Medicine in Houston. He earned his medical degree from the University of Kansas School of Medicine in Kansas City, KS. Dr. Cameron received his Bachelor of Science degree at Pittsburg State University in Pittsburg, KS.

*Board certified in Cardiovascular Disease and Cardiac Electrophysiology*

### Eugene J. Ichinose, MD, FACC

Dr. Ichinose specializes in interventional cardiology including cardiac catheterization, coronary angioplasty and related interventional procedures such as coronary stents, atherectomy, intravascular ultrasound and peripheral vascular interventional procedures. Dr. Ichinose is Director of Vein Services at Hillcrest Medical Center. He completed his Interventional and Clinical Cardiology Fellowships and his Internal Medicine Residency at the University of Massachusetts Memorial Health Care Center in Worcester, MA. Dr. Ichinose received his medical degree from Louisiana State University in New Orleans. He earned his Bachelor of Science degree from Texas Christian University in Fort Worth, TX.

*Board certified in Internal Medicine, Cardiovascular Disease, Interventional Cardiology and Nuclear Cardiology*

### Cristin M. Bruns, MD

Dr. Bruns is a specialist in Endocrinology, Diabetes and Metabolism at Oklahoma Heart Institute, with expertise in diabetes, thyroid disease (including thyroid cancer) and polycystic ovary syndrome. She completed her Internal Medicine Internship and Residency and Endocrinology Fellowship at the University of Wisconsin Hospital and Clinics in Madison, WI. Dr. Bruns earned her medical degree from Saint Louis University School of Medicine in St. Louis, MO and her Bachelor of Arts and Bachelor of Science degrees in biology from Truman State University in Kirksville, MO. Prior to joining Oklahoma Heart Institute, Dr. Bruns worked as a clinical endocrinologist at the Dean Clinic in Madison, Wisconsin.

*Board certified in Internal Medicine, Endocrinology and Metabolic Diseases*

### John S. Tulloch, MD

Dr. Tulloch is a noninvasive cardiologist with expertise in adult echocardiography, peripheral vascular imaging, nuclear cardiology, cardiac computed tomography and MRI. Dr. Tulloch is Director of the Cardiac and Vascular Ultrasound Department of Hillcrest Medical Center's Cardiovascular Diagnostics. He completed his Cardiovascular Fellowship at the University of Kansas Medical Center in Kansas City, KS. Dr. Tulloch's Internal Medicine Internship and Residency also were completed at the University of Kansas Medical Center. He earned his medical degree from Ross University School of Medicine in New Brunswick, NJ and received his Bachelor of Science degree in biology from Avila University in Kansas City, MO.

*Board certified in Internal Medicine, Cardiovascular Disease, Cardiovascular Tomography, and Nuclear Cardiology*

### Anthony W. Haney, MD, FACC

Dr. Haney is a noninvasive cardiologist with expertise in nuclear cardiology, echocardiography, peripheral vascular imaging and MRI. He also performs diagnostic cardiac catheterization. He completed his Cardiovascular Fellowship at the Medical College of Virginia in Richmond. Dr. Haney's Internal Medicine Internship and Residency were completed at the Mayo Clinic in Scottsdale, AZ. He earned is medical degree from the University of Oklahoma School of Medicine.

*Board certified in Internal Medicine, Cardiovascular Disease and Nuclear Cardiology*

### Ralph J. Duda, Jr., MD, FACP, FACE, FASH

Dr. Duda is a specialist in Endocrinology, Diabetes and Metabolism at Oklahoma Heart Institute, with expertise in diabetes, lipids, hypertension and thyroid diseases. Dr. Duda is Director of the Diabetes Education Center at Hillcrest Medical Center. He completed his Fellowship in Endocrinology and Metabolism at the Mayo Graduate School of Medicine, where he also completed his Residency in Internal Medicine. Dr. Duda received his medical degree from Northwestern University School of Medicine in Chicago, IL. He earned his Bachelor of Science degree from Benedictine University in Lisle, IL.

*Board certified in Internal Medicine, Endocrinology, Diabetes and Metabolism, Clinical Lipidology, Clinical Hypertension, Clinical Bone Densitometry and Thyroid Ultrasonography*

### Douglas A. Davies, MD, FACC, FASNC

Dr. Davies is a hospital-based cardiologist who provides continuity of care for patients admitted to Oklahoma Heart Institute – Hospital. He completed a Clinical Cardiology Fellowship and additional training in nuclear cardiology at the Medical College of Virginia, where he also completed his Internal Medicine and Residency programs. Dr. Davies received his medical degree from Johns Hopkins University School of Medicine in Baltimore.

*Board Certified in Internal Medicine, Cardiovascular Disease, Nuclear Cardiology and Cardiovascular Computed Tomography Angiography*

### Neil Agrawal, MD

Dr. Agrawal is a noninvasive cardiology specialist with expertise in adult echocardiography, nuclear cardiology, cardiac computed tomography and MRI. He completed his Cardiovascular Fellowship at the University of Vermont. Dr. Agrawal's Internal Medicine Internship and Residency were completed at the University of Louisville, and he earned his medical degree from St. George's University in Granada, West Indies. Dr. Agrawal completed his Bachelor of Science degree in biochemistry at the University of Texas at Austin.

*Board certified in Internal Medicine*

### Kamran I. Muhammad, MD, FACC, FSCAI

Dr. Muhammad is a subspecialist in interventional cardiology. In addition to expertise in traditional areas of interventional cardiology, such as coronary intervention (angioplasty, stent placement, atherectomy, intravascular imaging) and peripheral vascular and carotid artery intervention, Dr. Muhammad has a special interest and expertise in interventional therapies for structural and valvular heart disease including the percutaneous non-surgical replacement and repair of heart valves — TAVR and MitraClip. As such, he currently serves as the Director of the Structural Heart Disease Program at OHI.

With dedicated and advanced training in structural heart disease intervention from the world-renowned Cleveland Clinic, Dr. Muhammad has been a pioneer in this field in Oklahoma. He led a team of OHI physicians in performing the first transcatheter aortic valve replacements (TAVR) and first transcatheter mitral valve repairs (MitraClip) in Tulsa and the region. Under his direction, these programs are the most experienced and comprehensive programs of their kind in the state, providing our patients with expert care and class-leading technologies for the non-surgical treatment of structural and valvular heart diseases.

In addition to his clinical experience, Dr. Muhammad has authored many peer-reviewed articles and textbook chapters on important cardiology topics. He also serves as Clinical Associate Professor of Medicine at the University of Oklahoma College of Medicine — Tulsa.

Dr. Muhammad completed his Clinical Cardiology and Interventional Cardiology Fellowships at the Cleveland Clinic which included additional dedicated training in peripheral vascular and structural cardiac intervention. Dr. Muhammad completed his Internal Medicine Internship and Residency at Yale University where he was selected and served as Chief Resident. He earned his medical degree from the University of Massachusetts Medical School, graduating with top honors and election to the Alpha Omega Alpha (AΩA) honor society. Dr. Muhammad earned his Bachelor of Science degree in computer science from the University of Massachusetts, Amherst.

*Board certified in Internal Medicine, Cardiovascular Disease, Nuclear Cardiology and Interventional Cardiology*

### Arash Karnama, DO, FACC

Dr. Karnama is a specialist in interventional cardiology, including cardiac catheterization, coronary intervention, nuclear cardiology, echocardiography (TEE/TTE), cardioversion, peripheral angiography, peripheral intervention, carotid angiography, intravascular ultrasound, atherectomy, and PTCA/stenting for acute myocardial infarction. He is Director of the Cardiology Department at Hillcrest Hospital Claremore. Dr. Karnama completed his Interventional and Clinical Cardiology Fellowships at Oklahoma State University Medical Center and his Internal Medicine Internship and Residency at the Penn State Milton S. Hershey Medical Center in Hershey, PA. Dr. Karnama received his medical degree from Des Moines University in Des Moines, IA and his Bachelor of Arts degree from the University of Iowa in Iowa City.

*Board certified in Internal Medicine, Interventional Cardiology, Cardiovascular Disease, Nuclear Cardiology, and Cardiovascular Computed Tomography*

### Victor Y. Cheng, MD, FACC, FSCCT

Dr. Cheng joins Oklahoma Heart Institute after serving as cardiology faculty at Cedars-Sinai Medical Center and assistant professor at the University of California in Los Angeles for the past four years. Dr. Cheng is Director of the Cardiac Computed Tomography Department at Oklahoma Heart Institute and Hillcrest Medical Center. He is a specialist in noninvasive heart and vascular imaging, particularly in cardiac computed tomography (CT), a topic on which he has published numerous original research publications addressing quality, clinical use, and novel applications. Dr. Cheng's training included a Clinical Cardiology Fellowship and Advanced Cardiac Imaging Fellowship at Cedars-Sinai Medical Center, and an Internal Medicine Internship and Residency at the University of California in San Francisco. Dr. Cheng received his medical degree from Northwestern University in Chicago, IL and his Bachelor of Science degree from Northwestern University in Evanston, IL.

*Board certified in Internal Medicine, Cardiovascular Disease, Nuclear Cardiology, Echocardiography and Cardiovascular Computed Tomography*

### Jana R. Loveless, MD

Dr. Loveless is a sleep specialist, with expertise in the diagnosis and treatment of sleep disorders. She is Director of the Sleep Medicine Program at Hillcrest Hospital Claremore, Hillcrest Hospital Henryetta, and Hillcrest Hospital South. Prior to joining Oklahoma Heart Institute, Dr. Loveless was with Nocturna of Tulsa, Warren Clinic and Springer Clinic. She completed her Internal Medicine Residency program at the University of Oklahoma, Tulsa, where she was Chief Resident. She also earned her medical degree from, the University of Oklahoma, Tulsa. Dr. Loveless completed graduate studies at Texas Tech University, and she earned her Bachelor of Arts degree at Davidson College in Davidson, North Carolina.

*Board Certified in Internal Medicine and Sleep Medicine*

### Mathew B. Good, DO, FACC, RPVI

Dr. Good is an invasive/noninvasive cardiology specialist with expertise in adult echocardiography, nuclear cardiology, cardiac computed tomography, peripheral vascular ultrasound and MRI. He completed his Cardiovascular Fellowship at the University of Kansas Medical Center in Kansas City, KS, where he also completed his Internal Medicine Internship and Residency. Dr. Good received his medical degree from the Oklahoma State University Center for Health and Sciences in Tulsa and his Bachelor of Arts degree from the University of Colorado in Boulder.

*Board certified in Internal Medicine and Cardiovascular Computed Tomography*

### Stanley K. Zimmerman, MD, FACC, FSCAI

Dr. Zimmerman is the Director of the Catheterization Laboratory and Peripheral Vascular Services at Hillcrest Hospital South. He is the medical director of OHI vascular imaging laboratory. He is a specialist in interventional cardiology, including cardiac catheterization, coronary angioplasty, and related interventional procedures such as coronary stents, atherectomy, vascular ultrasound, and peripheral interventional procedures. Dr. Zimmerman specializes in complex vascular interventions, endovascular repair of abdominal aortic aneurysms and complex aorto-iliac disease, treatment of critical limb ischemia, and vascular management of arterial and venous based wounds.

He completed his interventional and Cardiovascular Fellowships at the University of Kansas Medical Center in Kansas City, KS, as well as his Internal Medicine internship and Residency. In addition, Dr. Zimmerman received his medical degree from the University of Kansas Medical Center and his Bachelor of Arts degree from the University of Kansas in Lawrence.

*Board certified in Internal Medicine, Cardiovascular Disease and Interventional Cardiology*

### Stephen C. Dobratz, MD, FACC

Dr. Dobratz specializes in diagnostic and interventional cardiology, including cardiac catheterization, peripheral angiography, pacemakers and defibrillators, cardioversion, cardiac nuclear studies, cardiac computed tomography, transesophageal echo and echocardiograms. Dr. Dobratz is Director of the Cardiac Catherization Laboratories at Hillcrest Hospital Claremore. He completed his Fellowship in Cardiology at Allegheny General Hospital in Pittsburgh, Pennsylvania. Dr. Dobratz completed his Internal Medicine Internship and Residency at the University of Arizona in Tucson. He earned his medical degree at Eastern Virginia Medical School in Norfolk and his undergraduate degree at James Madison University in Harrisonburg, Virginia.

*Board certified in Cardiovascular Disease*

### Michael Phillips, MD, FACC, FACS

Dr. Phillips is a Cardiovascular Thoracic Surgeon at Oklahoma Heart Institute. He completed his fellowship at Mid America Heart Institute in Kansas City, MO and his general surgery residency at the Mayo Graduate School of Medicine. He earned his medical degree from the University of Missouri. Dr. Phillips received his undergraduate degrees in Biology and Chemistry at William Jewell College in Liberty, MO.

*Board certified by in Thoracic and General Surgery*

### James B. Chapman, MD, FACC, FSCAI

Dr. Chapman is a specialist in interventional cardiology, including cardiac catheterization, coronary angioplasty and related interventional procedures such as stents, atherectomy, laser, intravascular ultrasound imaging and direct PTCA for acute myocardial infarction. He completed a Clinical Cardiology Fellowship St. Vincent Hospital and Health Care Center in Indianapolis, IN. He also completed his Internal Medicine Internship and Residency programs at St. Vincent. Dr. Chapman received his medical degree from Indiana University School of Medicine in Indianapolis and his Bachelor of Science degree from Indiana University in Bloomington, IN.

*Board certified in Internal Medicine, Cardiovascular Disease and Interventional Cardiology*

### Sandra E. Rodriguez, MD

Sandra Rodriguez is a noninvasive cardiology specialist with expertise in congestive heart failure and transplants. She completed an Advanced Heart Failure and Transplant Fellowship at the University of Colorado Hospital in Aurora, Colorado and her Cardiology Diseases Fellowship at Texas Tech University Health Sciences Center in Lubbock Texas. Dr. Rodriguez completed her Internal Medicine Residencies at Texas Tech and the Universidad El Bosque in Bogota, Colombia. She earned her medical degree from Medicine School, Escuela de Medicina "Juan N. Corpas," in Bogota.

*Board certified in Internal Medicine, Cardiovascular Disease and Advanced Heart Failure/Transplant Cardiology*

### Joseph J. Gard, MD, FACC, FHRS

Dr. Gard is a cardiologist who specializes in electrophysiology, complex ablation and atrial fibrillation management. He completed his Cardiac Electrophysiology Fellowship and his Cardiology Fellowship at the Mayo School of Graduate Medical Education in Rochester, Minnesota. Dr. Gard also performed his Internal Medicine Residency at Mayo. He earned his medical degree from the University of Nebraska in Omaha, Nebraska. Dr. Gard received his Bachelor of Science degree from Boston College in Chestnut Hill, Massachusetts.

*Board certified in Cardiovascular Disease, Internal Medicine, Electrophysiology and Clinical Cardiac Electrophysiology*

### Edward J. Coleman, MD, FACC, FAHA, FACS, FCCP

Dr. Coleman is a cardiovascular surgeon who specializes in cardiac, thoracic and vascular surgery. He completed his residency in cardiothoracic surgery at State University of New York at Buffalo in Buffalo, New York. He was Senior & Chief Resident at Mary Imogene Bassett Hospital/Columbia University College of Physicians & Surgeons in Cooperstown, New York. Dr. Coleman performed his Internship and Residency in general surgery at the University of Rochester School of Medicine & Dentistry in Rochester, NY. He earned his medical degree from State University of New York at Buffalo School of Medicine, Buffalo, New York. Dr. Coleman received his Bachelor of Arts degree from Norwich University in Northfield, Vermont.

*Board Certified in General Surgery and Thoracic Surgery*

### Michael B. Newnam, MD

Dr. Newnam is Director of Sleep Medicine at Hillcrest Medical Center and Hillcrest Hospital Cushing. He is a Board Certified specialist in the diagnosis and treatment of sleep disorders. He completed his Family Practice Internship & Residency programs at the Womack Army Medical Center in Ft. Bragg, NC. Dr. Newnam earned his medical degree from the University of Oklahoma and his Bachelor of Science degree from Oral Roberts University in Tulsa, OK.

*Board Certified in Family Medicine and Sleep Medicine*

### John M. Weber, MD, RPVI

Dr. Weber is a Peripheral Vascular Surgeon at Oklahoma Heart Institute who specializes in complex vascular disease. He offers both, open and endovascular treatment of arterial and venous disease. Areas of interest include open and endovascular treatment of aortic pathology, cerebrovascular surgery, limb salvage surgery, vascular access, and complex venous therapies. He completed his residency in Vascular Surgery at the Cleveland Clinic in Cleveland, Ohio. Dr. Weber earned his medical degree at the University of Oklahoma College of Medicine. He also completed his undergraduate degree at the University of Oklahoma.

### David Liff, MD

Dr. Liff is an interventional cardiologist who specializes in peripheral vascular disease as well as coronary interventional disease. He completed a Peripheral Interventional Fellowship at Ochsner Clinic in New Orleans, LA. and an Interventional Cardiology Fellowship at Hofstra/North Shore University /Long Island Jewish Hospital Center in New York. Dr Liff completed his Clinical Cardiology Fellowship at Emory University Hospital System in Atlanta, GA. He also performed his Internal Medicine Internship and Residency at Emory. Dr. Liff earned his medical degree from Ohio State University School of Medicine. He received his Bachelor of Science degree from the University of Michigan in Ann Arbor, MI.

*Board certified in Internal Medicine, Cardiovascular Disease and Interventional Cardiology*

### Saran Oliver, MD

Dr. Oliver is an invasive/noninvasive cardiology specialist with specific interests in adult echocardiography, nuclear cardiology, and women's cardiovascular health. She completed her Cardiovascular Fellowship at Scott and White Memorial Hospital in Temple, TX. Dr. Oliver performed her Internal Medicine Internship and Residency at the University of Texas Southwestern Medical Center in Dallas, TX. She also earned her medical degree from the University of Texas Southwestern Medical Center. Dr. Oliver attended Rice University in Houston, TX where she received her Bachelor of Arts degree in Sports Medicine.

*Board certified in Internal Medicine*
*Board eligible in Cardiovascular Medicine*

# Aorto-Iliac Occlusive Disease

*By John M. Weber, MD, RPVI*

Aorto-iliac occlusive disease is one of the most common forms of lower extremity arterial disease treated in the United States today, and enjoys some of the best long term results and patient satisfaction. Beginning in the 1940s, occlusive disease in this segment was treated with endarterectomy with varying degrees of success. However, today there are several open and endovascular approaches which have excellent long-term patency and lead to significant improvement or resolution of symptoms.

Patients with atherosclerotic occlusive disease of the aorta and iliac vessels typically have concomitant femoral-popliteal disease or tibial disease as well. However, the select group that has isolated aorto-iliac disease is usually younger smokers. Their symptoms are usually claudication, and are insidious in development due to the rich collaterals of the pelvis and abdominal wall. On the other hand, older patients with multi-level disease often have diabetes and hypertension. These patients typically present with rest pain or gangrene, and as such have much worse prognoses.

In the minority of cases where the disease is limited to the aorto-iliac segment, patients often complain of hip, thigh and buttock pain. This can be difficult to discern from degenerative disk disease and orthopedic complaints, which may also be present. Also, as many as 30% of men will complain of difficulty achieving or maintaining an erection. However, a good physical exam, checking the femoral pulses, will usually guide the practitioner to the correct diagnosis.

Once there is suspicion for peripheral arterial disease, the very first test to be ordered should be an Ankle Brachial Index with exercise. Not all patients can tolerate and exercise ABI, but often a resting ABI may be normal in patients with aorto-iliac occlusive disease due to the rich collateral blood flow and may only demonstrate a deficit with exercise. This test also establishes a baseline that can be used very efficiently to measure the effectiveness of revascularization and monitor the patient in follow-up.

Once the diagnosis is established or if further workup is warranted, axial imaging of the aorta with runoff should be next. While arterial angiography remains the gold standard, it is invasive and does not give the surgeon or interventionalist all the information needed for surgical planning.

*A newer and less invasive hybrid approach offered at OHI involves small groin incisions to treat the common femoral and distal external iliac arteries…it offers nearly the same 5 year primary patency rate as traditional aorto-bifemoral bypass surgery with no laparotomy and virtually no graft infection risk.*

Axial imaging allows for complex post processing necessary for stent graft measurements. It also can characterize associated thrombus, calcific plaques and aneurysms. Computed tomography allows for excellent spacial resolution, and magnetic resonance imaging may be preferable in patients with impaired renal function. The choice of which imaging modality to use should be left to the person performing the revascularization. Fortunately, at OHI we are able to offer excellent studies using both CT and MRI.

Once the diagnosis is made, the discussion with the patient as to how best to treat their aorto-iliac occlusive disease should take place. Patients with rest pain or gangrene need to be treated urgently. Claudicants, depending on the severity, may be treated conservatively with risk factor modification, medication and smoking cessation. This should be accompanied with a supervised walking program. However, it is acceptable to be very aggressive in the treatment of this disease. Many of the new hybrid and endovascular techniques have very favorable outcomes compared to traditional open bypass and can be tolerated by almost all patients.

The gold standard in the treatment of aorto-iliac occlusive disease is the aorto-bifemoral bypass. This procedure offers exceptional 5 year patency rates upwards of 90%. However it requires a laparotomy with its associated morbidity. There is also an approximate 7% risk of graft infection, which can be catastrophic. A newer and less invasive hybrid approach offered at OHI, termed the Endo ABF, involves small groin incisions to treat the common femoral and distal external iliac arteries, and angioplasty and stenting of the aorto-iliac segment. Sometimes a stent graft may need to be placed at the aortic bifurcation. This procedure offers nearly the same 5 year primary patency rate as traditional aorto-bifemoral bypass surgery with no laparotomy and virtually no graft infection risk. Patients often go home the very next day after surgery. Also, lesions limited to the aorto-iliac segment can often be treated percutaneously.

The specific surgery or intervention needed to treat aorto-iliac disease depends on many factors. Does the patient have critical limb ischemia or claudication? Is their disease limited to the aorto-iliac segment, or do they also have femoral-popliteal and tibial disease as well? Are they a suitable candidate for surgery or can they only tolerate a percutaneous procedure? Only a vascular specialist can make that decision once they have performed a thorough history and physical and relevant imaging studies are obtained.

*John Weber, MD is a Peripheral Vascular Surgeon at Oklahoma Heart Institute who specializes in complex vascular disease. He offers both open and endovascular treatment of arterial and venous disease. Areas of interest include open and endovascular treatment of aortic pathology, cerebrovascular surgery, limb salvage surgery, vascular access, and complex venous therapies.*

# Peripheral Vascular Disease and Limb Loss: Avoiding Amputation

*By Robert Smith, MD, MSc, FACC, FSCAI*

Over a million people in the United States are living with limb loss due to vascular disease. Annually, nearly 200,000 amputations are performed in the US, and nearly half of the individuals undergoing lower extremity amputation due to vascular disease will die within 5 years. This is higher than the mortality rates for breast cancer, colon cancer, melanoma, and congestive heart failure. Among people with diabetes who suffer a lower extremity amputation, over half will require amputation of the remaining leg within 2-3 years.

Despite rapid advances in endovascular techniques that improve blood flow, amputation rates remain alarmingly high, and over half of patients who receive amputation in the US will do so without having any type of vascular evaluation prior to amputation. Unlike factors associated with coronary heart disease, heart attack, and stroke, clinician and patient awareness regarding issues leading to lower extremity amputation are not widespread, and more education is needed.

Decisions regarding when to amputate a limb are determined by physician expertise and preference, and the threshold to perform lower extremity amputation is different among providers. No established or uniform treatment algorithm exists. Accordingly, geographic rates of lower extremity amputation vary widely across the country. According to Medicare data, amputation rates in Eastern Oklahoma are among the highest in the nation.

In patients with vascular disease, lower extremity amputation typically follows failed treatment of a wound on the foot. Wounds that culminate in the amputation of a leg often begin simply. Ingrown toenails, small cuts made with nail clippers, puncture wounds, and blisters are common examples. In patients with limited blood flow due to the buildup of cholesterol plaque, these minor problems can rapidly lead to severe infection or gangrene. If not dealt with quickly and effectively, they can ultimately threaten life and limb.

Patients with diabetes are at particularly high risk, as they often have compromised blood flow due to atherosclerosis, as well as diminished sensation in the legs and feet due to neuropathy. Other risk factors for limb threatening vascular disease include cigarette smoking, advanced age, renal disease, heart disease, lower socioeconomic status, and geographic region of the country. Patients at risk should ask their providers about the appropriateness of screening. Patients with reliably reproducible exertional leg pain (claudication), discoloration of the leg below the knee, or severely diminished pulses on physical exam are likely appropriate for some type of vascular imaging.

Routine vascular evaluations in patients with tissue loss (ischemic ulceration), slowly healing wounds of the toes or feet, recurrent lower extremity infections, or leg pain at rest are critical. For most affected patients, improving blood flow to the affected area is achievable, and can significantly reduce (although not eliminate) the risk of amputation. Techniques like angioplasty, stenting of arteries in the legs, and treatment of severely refluxing veins are commonplace and can often be performed in the outpatient setting. For refractory disease, aggressive endovascular techniques or

**Figure 1**

**Geographic Variation of Major Amputations of the Lower Extremity per 1,000 Medicare Enrolled**

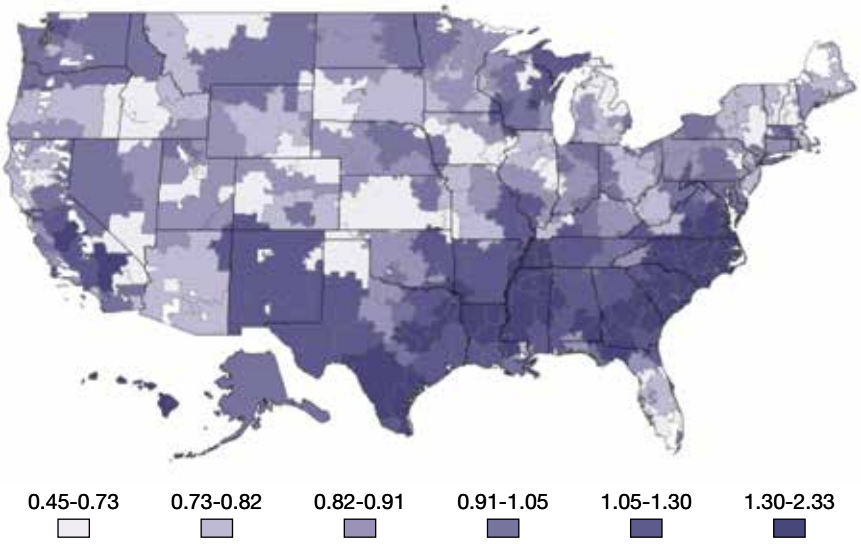


Source: Inpatient Medicare data, 2000-2008

*Amputation rates remain alarmingly high, and over half of patients who receive amputation in the US will do so without having any type of vascular evaluation prior to amputation.*

Figure 2

**Comparing Five-Year Mortality Rates of Amputation and Various Cancers**

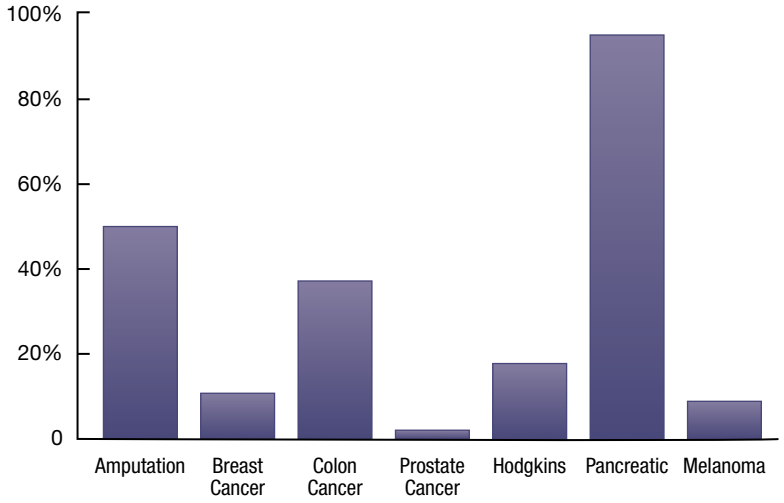


Source: American Cancer Society

*Available treatments for limb-threatening vascular disease by Oklahoma Heart Institute specialists include the latest endovascular and surgical techniques, hyperbaric oxygen therapy, optimal wound care by dedicated specialists, skin grafting, and more.*

lower extremity bypass surgeries are frequently possible.

Additionally, all amputations are not equal. The amputation of a toe does not carry the same mortality burden as does the amputation of a leg. Deciding the level of amputation is an inexact science, and it is important to try to minimize the need for a second surgery by doing too little. However, the higher up the amputation, the worse the outcomes tend to be. Preserving the knee joint, when possible, is associated with substantially lower mortality than that associated with above the knee amputation. Similarly, preserving the ankle joint is also associated with improved outcomes compared to amputations higher in the leg. Above the knee amputations are associated with the highest risk of death, with a 3 year mortality of 77% compared to a 3 year mortality of 63% in patients undergoing below the knee amputation. Amputations of the foot, forefoot (metatarsal), and toes are each associated with respectively more favorable mortality statistics.

In the modern era, proceeding to amputation without a thorough vascular evaluation, followed by an attempt at improving circulation, when applicable, is inexcusable. The stakes couldn't be higher. At the Oklahoma Heart Institute and Hillcrest Medical Center, every advanced modality for salvaging an affected limb is available. Our campuses at Hillcrest Medical Center and Hillcrest South are each equipped with dedicated peripheral vascular specialists, advanced imaging modalities, podiatrists, surgeons, advanced wound care specialists, and highly competent infectious disease specialists. This multi-modality approach to limb salvage is critical to success, and certainly does not exist in many centers throughout Oklahoma or across the country. Available treatments for limb-threatening vascular disease include the latest endovascular and surgical techniques, hyperbaric oxygen therapy, optimal wound care by dedicated specialists, skin grafting, and more. We cannot save every limb, but we can certainly do better. Health care providers and patients alike should demand that these types of services are fully utilized prior to consideration of amputation. With the abysmal mortality data associated with lower extremity amputation, a life may depend on it.

*Robert Smith specializes in interventional cardiology including cardiac catheterization, coronary angioplasty, and related interventional procedures such as coronary stents, atherectomy, intravascular ultrasound, and peripheral vascular interventional procedures.*

**References:**

1. Fisher ES, Goodman DC, Chandra A. Disparities in Health and Health Care among Medicare Beneficiaries: A Brief Report of the Dartmouth Atlas Project. Robert Wood Johnson Foundation, 2008.
2. HCUP Nationwide Inpatient Sample (NIS). Healthcare Cost and Utilization Project (HCUP). Rockville, MD: Agency for Healthcare Research and Quality; 2009.
3. Owings M, Kozak LJ, National Center for Health S. Ambulatory and Inpatient Procedures in the United States, 1996. Hyattsville, Md.: U.S. Dept. of Health and Human Services, Centers for Disease Control and Prevention, National Center for Health Statistics; 1998.
4. Pandian G, Hamid F, Hammond M. Rehabilitation of the Patient with Peripheral Vascular Disease and Diabetic Foot Problems. In: DeLisa JA, Gans BM, editors. Philadelphia: Lippincott-Raven; 1998.
5. Robbins JM, Strauss G, Aron D, Long J, Kuba J, Kaplan Y. Mortality Rates and Diabetic Foot Ulcers. Journal of the American Podiatric Medical Association2008 November 1, 2008;98(6):489-93.
6. Swaminathan A, Vemulapalli S, Patel MR, Jones WS. Lower extremity amputation in peripheral artery disease: improving patient outcomes. Vascular Health and Risk Management. 2014;10:417-424.
7. Ziegler-Graham K, MacKenzie EJ, Ephraim PL, Travison TG, Brookmeyer R. Estimating the Prevalence of Limb Loss in the United States: 2005 to 2050. Archives of Physical Medicine and Rehabilitation2008;89(3):422-9.

# Catheter Based Treatment for Venous Insufficiency and Chronic Venous Ulceration

*By Robert Smith, MD, MSc, FACC, FSCAI*

Venous insufficiency is a condition in which the leg veins do a poor job of sending deoxygenated blood back up to the heart, resulting in chronic congestion of the lower extremities. This chronic congestion can manifest in a variety of ways, including dull aching or heaviness of the legs, itching, burning, swelling, skin discoloration, and chronic ulceration. Varicose veins often appear when chronic congestion has been present for quite some time, but not all patients with this condition develop them. Varicose veins may also itch, burn, or contribute to the development of superficial blood clots (thrombophlebitis).

Several risk factors for the development of venous insufficiency exist, though perhaps the most important is family history: most patients who develop symptomatic venous insufficiency will find a parent, grandparent, or sibling with the same condition. Although the understanding of genetic factors contributing to venous insufficiency is imprecise, the main issue appears to be the amount of collagen in the valves that keep blood flowing through the veins, and perhaps in the walls of the veins as well. Other important risk factors include obesity, pregnancy, and prior history of deep vein thrombosis.

Venous insufficiency is extremely common, with some estimates suggesting that 1 in 4 people will develop it at some point in life. Most of these patients will not require treatment. For some, however, venous insufficiency causes a great deal of discomfort. Patients with severe venous insufficiency sometimes develop chronic wounds on the lower legs called stasis ulcers. When other illnesses like diabetes or peripheral arterial disease are also present, stasis ulcers can lead to infection, gangrene, and amputation. For patients that are highly symptomatic (with or without varicose veins), and for those with stasis ulcers, effective treatments are available.

If chronic venous insufficiency is suspected, the diagnosis may be confirmed via ultrasound. Specialized ultrasound studies called venous mapping studies can identify the location of incompetent veins and provide important information regarding the severity of the problem. If the ultrasound study reveals significant insufficiency, and the patient is highly symptomatic, treatment will likely be recommended. Common treatment options include catheter ablation of refluxing veins, sclerotherapy, and phlebectomy. Prior to proceeding with any of these therapies, insurance providers typically require the documentation of at least three months of consistent compression stocking use. Often, insurance providers will also require documentation of other conservative therapies, such as leg elevation and the use of over-the-counter pain medicines. Unfortunately, these more conservative measures rarely deal with the problem effectively.

*Most patients who develop symptomatic venous insufficiency will find a parent, grandparent, or sibling with the same condition.*

**Normal and incompetent venous valves**

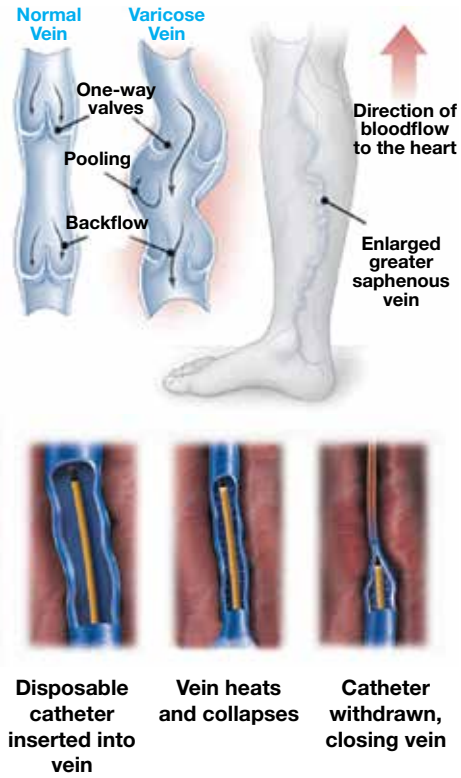


Catheter ablation, when appropriate, is performed in the outpatient setting, typically with IV sedatives to help relax the patient. Using ultrasound guidance and local anesthetic, the refluxing vein is entered with a needle and a large tube is placed in the vein. A thin catheter is then passed through the tube and carefully positioned within the diseased vein. Following catheter placement, fluid is gently pumped into the leg in order to numb the leg and insulate the vein. When all of this preparation is complete, the catheter ablation typically takes less than 5 minutes. The complication rate of this procedure is exceedingly low, but follow-up ultrasound studies are typically performed 3-4 days following the procedure, and sometimes again a few weeks later. The purpose of the follow-up studies is to confirm vein closure and screen for deep vein thrombosis (DVT). On rare occasions, a non-occlusive DVT is identified, and a few months of anticoagulant therapy with warfarin, eliquis, or xarelto is typically recommended. It is important to note that there have been no reports of severe or life threatening complications associated with this procedure, and it is generally regarded by patients and physicians alike as a fairly simple invasive procedure. For those with large and well-established varicose veins, additional treatment with sclerotherapy and phlebectomy is often required following catheter

**During catheter ablation of a refluxing vein, heat is applied to the inside of the vein, resulting in permanent closure of the vein.**

**Before and after catheter ablation with phlebectomy and sclerotherapy**

ablation.

Sclerotherapy is simple, and involves injection of medicine into the lumen of veins that are too small or tortuous to be treated with a catheter. This technique is also performed under ultrasound guidance. It is important that the treating physician be judicious in the use of these injectable medicines, as they occasionally cause small areas of deep vein thrombosis. When DVT occurs as a complication of sclerotherapy, it is most often asymptomatic, and typically occurs in the small veins near the ankle. DVT in these areas is not dangerous to the patient, and there is no significant risk of these causing major issues, though a few months of anticoagulant therapy is typically recommended in these cases as well. One in ten patients will experience some degree of brownish skin discoloration above the treated vein following sclerotherapy. In about 90% of patients, this fades over time, although it may be present for several months following the procedure.

Phlebectomy is a technique performed with local anesthetic that involves making tiny incisions over large varicose veins. A special tool is then inserted through the incisions and used to retrieve varicose veins from the tissue beneath the skin and pull them to the surface. Gentle traction is then applied in order to remove the veins. It is not unusual for patients with large varicose veins to require 10 or more small incisions. Although minor bleeding under the skin may occur following this procedure, and the patient may be sore for a few days afterward, the complication rate is also extremely low. Complications include minor persistent bleeding or development of a skin infection at one of the incision sites. If either of these occur, they are typically treated with simple measures.

At Oklahoma Heart Institute's SouthPointe Office, each of these procedures is performed in a dedicated suite built solely for the purpose of treating venous disease. Our experienced team of physicians, ultrasound technicians, X-ray technicians, nurses, and cath lab staff have performed thousands of these procedures, and are prepared to offer the best possible patient experience.

**Skin discoloration due to venous disease**

**Venous Ulcer**

*Robert Smith specializes in interventional cardiology including cardiac catheterization, coronary angioplasty, and related interventional procedures such as coronary stents, atherectomy, intravascular ultrasound, and peripheral vascular interventional procedures.*

## References:


1. College of Certified Wound Specialists. 2009. 1:12-19
2. Cornu-Thenard A et al. "Importance of the familial factor in varicose disease. Clinical study of 134 families" J DermatolSurgOncol 1994
3. Santler, R., Ernst G., Weiel, B. "Statistischesuber der varikosenSymptomenkomplex" Hautarzt 1956; 10: 460-3
4. Jones L et al. "Neovascularization is the principal cause of varicose vein recurrence: results of a randomized trial of stripping the long saphenous vein" EurJEndovascSurg 1996; 12:442-5.
5. Rutgers PH et al. "Randomized trial of stripping versus high ligation combined with sclerotherapy in the treatment of the incompetent greater saphenous vein" Am J Surg 1994;168:311-15.
6. Dwerryhouse S, Davies B, Harradine K, Earnshaw JJ. "Stripping the long saphenous vein reduces the rate of reoperation for recurrent varicose veins: five-year results of a randomized trial" J Vasc Surg. 1999 Apr;29(4):589-92.
7. Rasmussen L et al. "Randomized trial comparing endovenous laser ablation of the great saphenous vein with high ligation and stripping in patients with varicose veins" J VascSurg 2007;46:308-15
8. Darwood RJ et al. "Randomized clinical trial comparing endovenous laser ablation with surgery for thetreatment of primary great saphenous varicose veins" Br J Surg 2008;95:294-301
9. Kalteis M et al. "High ligation combined with stripping and endovenous laser ablation of the great saphenous vein: Early results of a randomized controlled study" J Vasc Surg. 2008;47:822-29
10. Ogawa T et al. "Endovenous Laser Ablation Compared With Stripping – Multi-Center RCT in Japan" Poster presentation at the American Venous Forum February 2008, Charleston, SC
11. Merchant et al. "Long-term Outcomes of Endovenous Radiofrequency Obliteration of Saphenous Reflux as a Treatment for Superficial Venous Insufficiency" J VascSurg 2005;42:502-9.
12. Proebstle et al. "Treatment of the incompetent great saphenous vein by radiofrequency powered segmental thermal ablation: First clinical experience" J VascSurg 2008;47:151-6.

# May Thurner Syndrome

*By Eugene Ichinose, MD*

Venous stasis syndrome involves the development of persistent dependent leg edema with leg pain, skin darkening and swelling. It will usually worsen as you stand throughout the day and improve overnight as you rest. As the skin and tissue of the leg develop vascular changes, the most severely affected may develop venous ulcers.

Venous stasis syndrome is a major health problem, with an annual incidence of 76 per 100,000. The socio-economic impact of chronic venous diseases is high, with an estimated annual direct cost of $200 million in the United States. Indirect costs are also substantial: at least 2 million workdays are lost annually in the US due to venous ulcer. Furthermore, venous stasis syndrome adversely impacts quality of life.[1]

Venous stasis syndrome commonly occurs independently of a deep vein thrombosis. The underlying pathophysiology of venous stasis syndrome is excess fluid in the legs which expands the volume within the legs, stretching the tissue including the muscle, fascia, and ultimately the skin. This results in a nagging persistent ache, fatigue in the leg that seems to be worse as the volume accumulates through the day. The symptoms are lessened by external compression that limits the amount of expansion, elevation that promotes drainage, and repeat ankle flexion (also called walking or calf raises).

Since venous stasis syndrome can occur in individuals with or without a prior history of deep vein thrombosis, the mechanism leading to leg venous hypertension may be different.

Lower extremity venous hypertension may be due to elevated central venous pressure caused by central obesity, pregnancy, congestive heart failure, pulmonary hypertension or right heart failure. Venous hypertension may be due to obstruction or restriction of venous flow out of the legs, accumulation of fluid in the leg from venous reflux, or impaired pump function (lack of flexion of the ankle and calves ).

In 1851, Rudolf Virchow observed the left sided predominance

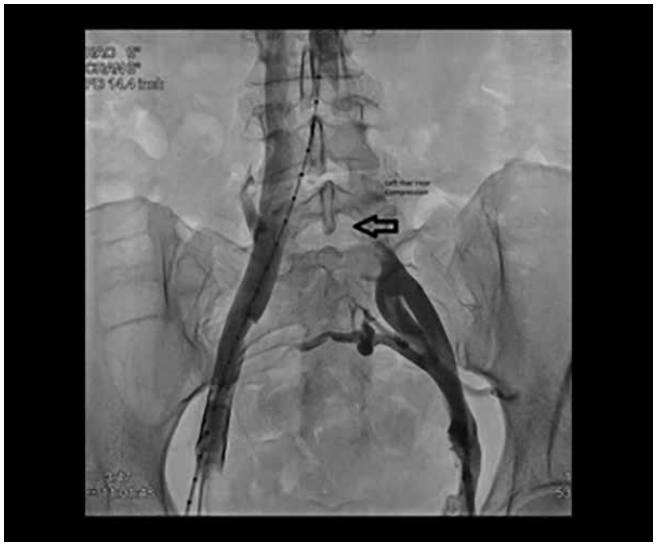

**A 38 year old female with history of DVT involving the left leg. She had pain and swelling on the left leg which worsened with standing for long periods of time. This venogram demonstrates the left iliac vein without contrast, because of the right and left iliac arteries causing compression.**

**This venogram demonstrates the results of placing a stent within the left iliac vein, promoting unobstructed flow from the left leg.**

of deep venous thrombosis of the legs and proposed compression of the left common iliac vein by the common iliac artery as the underlying cause. More than a century later, May and Thurner noted the presence of venous webs, or "spurs," in the left common iliac vein in 22% of autopsies.

They attributed these spurs to scarring from repetitive compression of the common iliac vein by pulsations of the overlying common iliac artery. Fifty percent compression of the iliac vein has been documented in approximately half of patients with left iliac vein thrombosis and up to 25% of patients who are asymptomatic. It is unclear what percent of people with asymptomatic compression will have a deep vein thrombosis. This condition of iliac vein compression by the overriding iliac artery is referred to as May Thurner Syndrome.

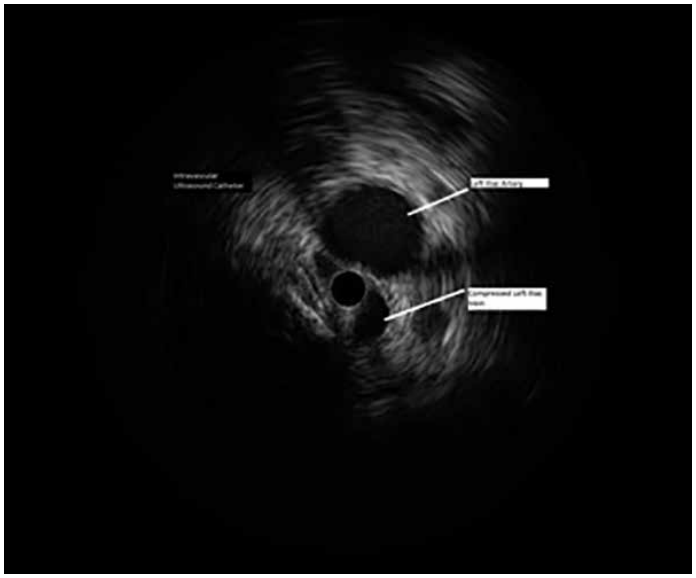

**This intravascular ultrasound image demonstrates the imaging catheter in the compressed left iliac vein with an iliac artery laying on top.**

Obstruction of the femoraliliocaval veins can cause chronic venous hypertension and high venous pressures, resulting in inflammatory changes causing physical limitations and chronic pain.

Common symptoms include pain in the lower extremities, vulva, pelvis, or low back pain at rest, standing or walking, occasionally pain with intercourse. One-sided lower extremity edema, heaviness and recurrent cellulitis are commonly associated with obstruction of the femoraliliocaval vein.

When these symptoms limit activity and enjoyment, it is important to consider venous obstruction. Medical management of venous obstruction include leg elevation, compression with elastic or inelastic devices, and compression pumps. [3]

Diagnosing venous obstructive disease can include noninvasive and invasive venous imaging. Prospective studies have suggested that the sensitivity and specificity of magnetic resonance venography for the detection of pelvic deep-vein thrombosis is similar to the sensitivity and specificity of invasive venography.

Invasive venography through femoral or popliteal venous access remains the gold standard for the diagnosis of iliac vein compression syndrome. It can demonstrate venous compression as well as the diversion of venous flow through pelvic collateral vessels. Intravascular ultrasound imaging has become an increasingly important adjunct to venography in the diagnosis of iliac vein compression syndrome.

There is robust clinical evidence supporting the alleviation of venous obstruction using balloon angioplasty and stenting, if feasible. Stenting can relieve symptoms and is associated with a low recurrent stenosis.

Raju and Ward reported on 107 iliac limbs treated with balloon angioplasty and stenting for chronic iliofemoral vein obstruction in 95 patients aged 80 to 96 years, median 83 years. Patients were selected for treatment if they failed to respond to compression or if compression was difficult or impossible to achieve. Primary and assisted primary patency at 5 years were 52 and 90%, respectively. Pain completely resolved in 43% and the pain score significantly improved in 71%. Lower extremity swelling resolved completely in 25% and improved significantly in 63%. Seventy percent who experienced prior LE cellulitis had no recurrence and 61% of active VLUs healed. There was no mortality and there were few minor complications.

Raju concluded that iliac vein stenting "appears to offer a safe and effective option in octogenarians and nonagenarians when compression therapy fails."

Stenting of the compressed iliac vein is done in the outpatient setting using a 10-11f sheath. The patient may experience lower back pain, typically managed with ibuprofen for 1-5 days. There is no lifting over five pounds for three day, then activity as tolerated. No submersion in hot tubs, lakes or rivers for at least a week, although you may shower within the first twenty four hours, keeping close watch of the access site to keep the area clean and dry.

Follow up ultrasound is typically done in four weeks, three months and six months. Aspirin has been adequate for anti-platelet therapy if not associated with deep vein thrombosis.

Otherwise, in the setting of a deep vein thrombosis, anticoagulation is typically done for 3-6m or longer, depending on the patient's clinical factors.

*Eugene Ichinose, MD specializes in interventional cardiology including cardiac catheterization, coronary angioplasty and related interventional procedures such as coronary stents, atherectomy, intravascular ultrasound and peripheral vascular interventional procedures.*

## Bibliography:

1. Risk Factors and Underlying Mechanisms for Venous Stasis Syndrome: A Population-Based Case-Control Study Aneel A. Ashrani, M.B., B.SVasc Med. 2009 November ; 14(4): 339–349.
2. Patel NH, Stookey KR, Ketcham DB, Cragg AH. Endovascular management of acute extensive iliofemoral deep venous thrombosis caused by May-Thurner syn- drome. J Vasc Interv Radiol 2000;11:1297- 302.
3. O'Sullivan GJ, Semba CP, Bittner CA, et al. Endovascular management of iliac vein compression (May-Thurner) syndrome. J Vasc Interv Radiol 2000;11:823-36.

# The AngioVac Procedure

*By Eugene J. Ichinose, MD, FACC*

Veins, the vessels that return blood to the heart, veins, can become occluded by thickened blood. In the early stages, the thickened blood is the texture of jello. Over time, it becomes the texture of peanut butter, then the texture of caulk, thus becoming more challenging to remove.

A clot is thickened blood blocking up a vessel. When it is in the pelvis or hip, this causes the thigh and leg to swell since the blood cannot drain. Traditionally, this has been treated by thinning the blood, which prevents the clot from extending. The body is then able to begin slowly dissolving the clot. However, waiting for the body to dissolve the clot allows time for the clot to move to the lung, and promotes chronic discomfort and swelling. Many times the body is unable to dissolve a significant amount of clot.

In 2012, it was found that infusing a clot-dissolving medication decreased long term chronic swelling and discomfort of the leg but was associated with significant bleeding risks.

Because of the increased bleeding risk associated with attempts to dissolve clots, newer techniques were developed. The AngioVac Procedure removes more clot, promptly restoring blood flow, and gaining at least similar results with less risk of bleeding.

The angiovac DVT procedure involves general anesthesia and recovery in the ICU. During the procedure the patient is unconscious, and access is gained in multiple sites - right/left neck, groin, behind the knee. By carefully inserting a 24f sheath in the right internal jugular vein a circuit of blood flow is created where blood clots can be sucked from the iliofemoral vein, or IVC into the cannula and filtered out, with the remaining blood returned to the patient. Photo 1: typical filter after a deep vein thrombosis removal.

There is some blood loss and it is not uncommon to need a blood transfusion or to be anemic. We try to achieve a careful balance between keeping the blood thin and trying to heal the access sites. A follow up vascular ultrasound is done of the legs within the first week. Screening for cancer and for blood clotting disorders is performed as an outpatient.

If a filter was placed in the inferior vena cava, an appointment will be made to assess removing it within the first 3-6month. Activity is limited to no lifting >5lb for 5 days, then as tolerated.

*Eugene Ichinose, MD specializes in interventional cardiology including cardiac catheterization, coronary angioplasty and related interventional procedures such as coronary stents, atherectomy, intravascular ultrasound and peripheral vascular interventional procedures.*

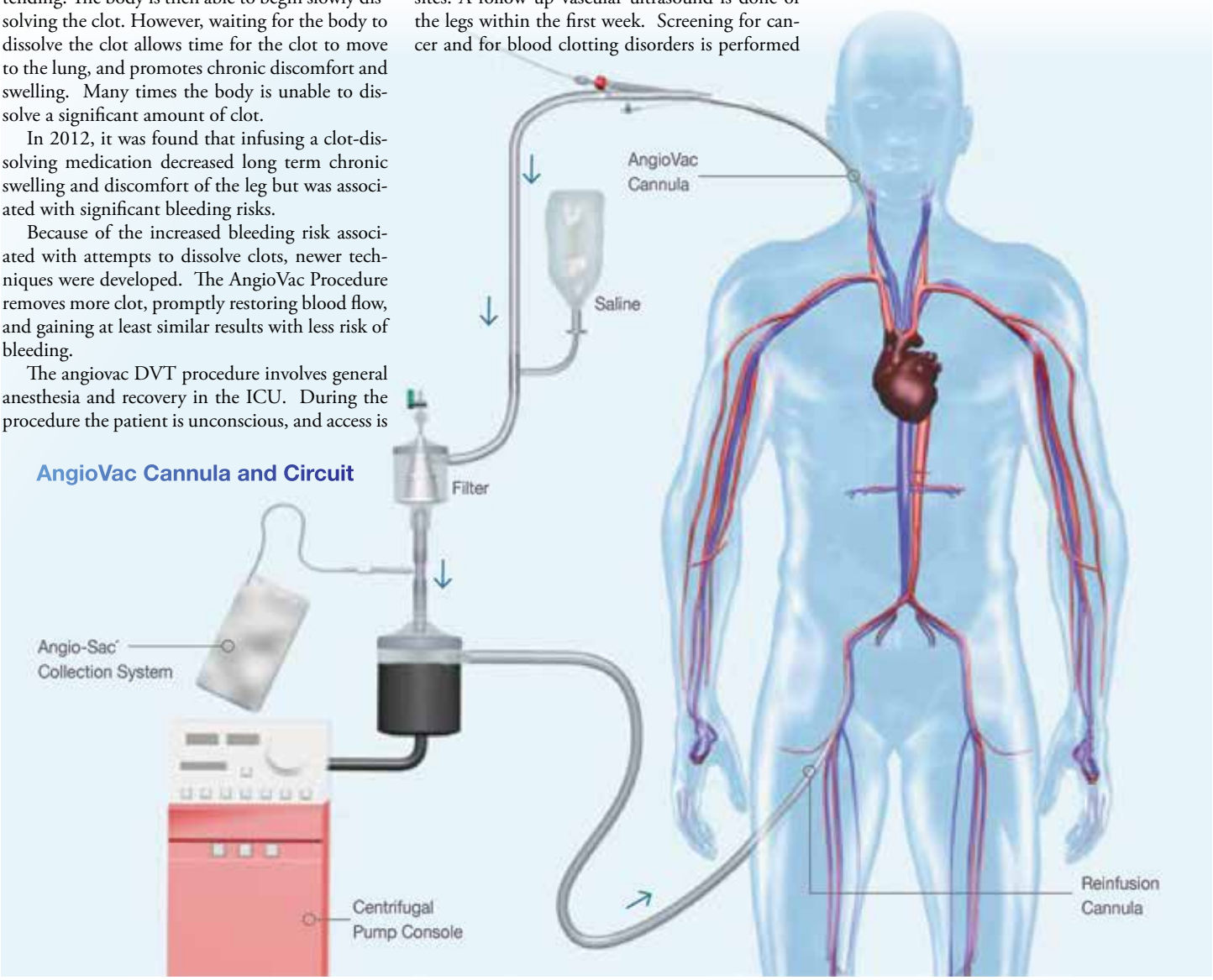

# Peripheral Artery Disease and the Wound Center at Hillcrest Hospital South

Chronic wounds affect 6.7 million people in the Unites States today. Currently, our nation spends 50 billion dollars annually on the treatment of these wounds. There are many different types of vascular disease, however Peripheral Arterial Disease (PAD) is one of the most common conditions we face as Americans and it is continuing to rise at an alarming rate. Currently, 8-12 million Americans suffer from PAD.

PAD develops when the arteries that supply oxygen-rich blood to the internal organs, arms and legs become completely or partially blocked as a result of atherosclerosis (buildup of plaque). PAD can increase the risk of heart attack, stroke, amputation and possibly death.

## PAD Risk Factors

- Coronary Artery Disease
- High blood sugar
- High cholesterol
- High blood pressure
- Obesity
- Physical inactivity
- Smoking or use of tobacco products

Those who smoke or have diabetes mellitus have the highest risk of complications from Peripheral Vascular Disease because these risk factors also cause impaired blood flow. While some with PAD may experience no symptoms, others may experience the following:

## PAD Symptoms

- Non-healing wounds over pressure points, such as heels, ankles, tips of fingers and toes
- Changes in the skin, including decreased skin temperature, or thin, brittle shiny skin on the legs and feet
- Diminished pulses in the legs and the feet
- Gangrene (dead tissue due to lack of blood flow)
- Hair loss on the legs
- Impotence
- Numbness, weakness, or heaviness in muscles
- Pain (described as burning or aching) at rest, commonly in the toes and at night while lying flat
- Pallor (paleness) when the legs are elevated
- Reddish-blue discoloration of the extremities
- Restricted mobility
- Severe pain when the narrowing of the artery is significant or totally blocked
- Thickened opaque toenails


**Dr. Ronald Brown and the Staff of the Advanced Wound Center@ Hillcrest Hospital South Increase Awareness of Peripheral Vascular Disease During February National Heart Month**

Chronic Wounds of the lower extremity are very common in people with PAD. If left untreated, these chronic wounds can progress to more serious complications, which may result in the loss of limb. Adequate blood flow is a necessary component of wound healing; without it, it is impossible for wounds to heal. Exercise and good nutrition are also very important in wound healing

Dr. Ronald D. Brown, of the Advanced Wound Center at Hillcrest Hospital South recommends the following action steps to help manage PAD:

- Lifestyle changes such as quitting smoking, correcting blood pressure and cholesterol numbers
- Smoking, high blood pressure and high cholesterol are major risk factors for the development of PAD. Managing these conditions can help improve blood circulation.
- Develop healthy eating habits and an exercise plan
- Exercising can help increase the circulation and reduce pain in the lower extremities. Walking, hiking and bike riding are good exercise options. A personal trainer can help tailor a custom workout plan that best fits a person's needs.
- Medications
- Always consult with a physician about which medications may help PAD and if they are needed.
- Special procedures and surgeries

In some severe cases of PAD, surgery or endovascular therapy may be needed to open arteries that have narrowed. The Wound Center at Hillcrest South works hand in hand with the specially trained Vascular Surgeons and Interventional Cardiologists at Oklahoma Heart Institute. These physicians specialize in performing revascularization procedures when needed to restore healthy blood flow. In many cases Hyperbaric Oxygen Therapy is beneficial in treating wounds of this type.

## Hyperbaric Oxygen Therapy

During this specialized treatment the patient breathes 100% oxygen in a pressurized chamber. This treatment supplies the body with at least 10 times its normal supply of oxygen to help repair damaged tissue. Hillcrest Hospital South is proud to offer this new innovative therapy.

**For more information about PAD, Hyperbaric Oxygen Therapy and the Treatment of Chronic Wounds:**

*8803 South 101st East Ave., Suite 160 • Tulsa, OK 74133*

*Phone: 918-294-HEAL(4325) Fax: 918-294-4349 • Hours: Monday-Friday 8:00 am - 4:30pm*

## MEXICAN-STYLE GRILLED CORN Serves 6

In a nod to the corn-on-the-cob often served by street vendors in Mexico, sweet corn is brushed with a smoky chipotle spread before grilling, and then finished with crumbled cheese, cayenne and a squeeze of fresh lime juice.

**1/4 cup crème fraîche**

**1/4 cup light mayonnaise**

**1/2 teaspoon fine sea salt**

**2 canned chipotles in adobo sauce, seeded**

**6 ears corn, husked**

**1/2 cup queso fresco or grated Parmigiano Reggiano**

**1/8 teaspoon cayenne pepper**

**1 lime, cut into wedges**

Preheat a grill to medium-high heat. Meanwhile, put crème fraîche, mayonnaise, salt and chipotles in adobo in a food processor and pulse just until smooth; transfer to a bowl. Generously brush mixture on corn and grill, turning occasionally, until deep golden brown, 7 to 9 minutes.

Brush remaining crème fraîche mixture on corn, then sprinkle all over with queso fresco and cayenne. Serve with lime wedges on the side to squeeze over the top.

## HONEYDEW AND POBLANO SALAD WITH SMOKED SALT AND MINT Serves 4 to 6

This melon salad makes a terrific side or starter for a warm-weather meal. Make an even smokier version of this salad by first charring the poblano whole on the grill or over the flame of a gas burner before removing the stem and seeds.

**1 1/2 tablespoon lime juice**

**1 poblano pepper, seeded and diced***

**1/2 honeydew melon, peeled, seeded and diced (about 5 cups)**

**2 small pickling (Kirby) cucumbers, diced**

**1/4 cup chopped fresh mint**

**1/4 teaspoon smoked sea salt**

In a large bowl, toss together lime juice and poblano. Add honeydew, cucumber and mint, and toss again. Sprinkle with smoked salt and serve.

* If poblano peppers aren't available, substitute a small green bell pepper and a pinch of cayenne.3 comments

## GRILLED TUNA NIÇOISE SALAD

Serves 4 to 6

Enjoy this classic Mediterranean composed salad of grilled tuna, fresh veggies and hard-boiled eggs. Serve with warm slices of whole wheat bread on the side, if you like

**2 tablespoons Champagne vinegar**

**1 tablespoon chopped fresh tarragon**

**1 teaspoon Dijon mustard**

**1 small shallot, finely chopped**

**1/2 teaspoon fine sea salt**

**1/4 teaspoon ground black pepper**

**1/4 cup extra-virgin olive oil**

**1 (1-pound) fresh, or frozen and thawed, tuna steak**

**Extra-virgin olive oil cooking spray**

**1 1/2 pound small new potatoes, boiled or steamed until tender and cooled**

**1/2 pound green beans, trimmed, boiled or steamed until tender and cooled**

**1 cup halved cherry tomatoes**

**1/2 cup pitted Niçoise olives**

**1/2 cup thinly sliced red onion**

**1 hard boiled egg, peeled and cut into wedges**

In a small bowl, whisk together vinegar, tarragon, mustard, shallot, salt and pepper. Slowly whisk in oil to make a vinaigrette. Put tuna into a wide, shallow dish, drizzle all over with 2 tablespoons of the vinaigrette, cover and chill for 30 minutes. Reserve remaining vinaigrette.

Prepare a grill for medium heat cooking. Arrange tuna on the grill and cook 5 to 7 minutes on each side, or until tuna reaches desired doneness. Transfer to a plate. When cool enough to handle, flake into large pieces. Arrange tuna, potatoes, green beans, tomatoes, olives, onion and egg on a large platter and serve with reserved vinaigrette on the side to spoon over the top.

Oklahoma Heart Institute

# Screening Tests That Can Save Your Life and Prevent Heart Attack and Stroke

No physician referral required.
Open to the general public.
Evening appointments available.

Call today for your appointment!

# 918.592.0999

Exclusively at Oklahoma Heart Institute

**The Cardiovascular Screening Program is provided by Oklahoma Heart Institute, a trusted name in Northeast Oklahoma for more than 20 years.**

**918.592.0999 • 1265 South Utica Ave • 9228 South Mingo**
**www.OklahomaHeart.com**

## 5 Easy Ways to Live Longer

According to the American Heart Association, many people experience no symptoms before having a heart attack or stroke.

A series of simple screening tests by trained experts in cardiovascular disease can identify problems before symptoms develop, preventing issues down the road. *The cost is low. The tests are simple and fast. Aren't you worth it?*

### 1 Carotid Artery Evaluation

Strokes rank 3rd among all causes of death behind diseases of the heart and cancer. To assess your risk for stroke, an ultrasound probe is placed on your neck to screen for blockages in your carotid arteries which supply blood to the brain. This is also a marker of heart attack risk. **15 minutes, $40**

### 2 Cardiac Function Evaluation

To analyze cardiac function and calculate your Ejection Fraction (the amount of blood your heart is able to pump), an ultrasound probe will be positioned at various locations on your chest. **15 minutes, $40**

### 3 Abdominal Aorta Evaluation

Most abdominal aneurysms are asymptomatic. They're the 10th leading cause of death in males over 55. To screen for aneurysm, an ultrasound probe is used to analyze your abdominal aorta. **15 minutes, $40**

### 4 Ankle/Brachial Index

Blood pressures are obtained from your legs and arms to screen for peripheral artery disease. It not only assesses circulation to the legs, but also is a marker of heart attack risk. **15 minutes, $40**

### 5 Cardiac Calcium Score

Coronary plaque can build up silently for years, and if untreated can cause blockages and heart attacks. This test measures the calcified plaque in the coronaries and is an indirect measure of the total amount of plaque in the coronaries. A multi-slice CT scanner takes a series of pictures of your heart in just a few seconds. **15 minutes, $99**

## Living Longer Just Got Easier.

**It's fast, accurate, painless and you don't need a physician's referral.**

Combine Screenings and Save:
Schedule screenings 1 - 4 and receive a $20 discount.

OHI-FLY-1209-0011

OKLAHOMA HEART INSTITUTE
1265 S. Utica Avenue
Suite 300
Tulsa, OK 74104

Presorted Standard
U.S. Postage Paid
Tulsa, OK
Permit No. 2146

# Through the Years

Heart disease strikes young and old alike, taking many shapes and forms.
At Oklahoma Heart Institute, our specialists treat heart problems that occur through all ages.
From a rhythm disturbance in young athletes, to heart attacks in the middle aged,
to valve replacement in the elderly, the doctors of OHI have the technology
and expertise to care for you all through your years.

For a continuum of heart care that stands the test of time, trust the doctors of
Oklahoma Heart Institute.

Oklahoma Heart Institute

Nationally Recognized Cardiovascular Specialists | **918.592.0999** | **www.oklahomaheart.com**

1120 SOUTH UTICA AVE. Oklahoma Heart Institute (The Heart Hospital) | 1265 SOUTH UTICA (Utica Physicians Office) | 9228 SOUTH MINGO (SouthPointe Physicians Office) | 8801 SOUTH 101ST E. AVE. (Hillcrest South)